

Original research article

Evaluation of single intratesticular injection of calcium chloride for nonsurgical sterilization in adult albino rats

Kuladip Jana, Prabhat Kumar Samanta*

Department of Veterinary Surgery and Radiology, West Bengal University of Animal and Fishery Sciences, Calcutta 700 037, West Bengal, India

Received 11 December 2003; revised 9 June 2005; accepted 13 July 2005

Abstract

Objective: To investigate a method of chemical sterilization and its efficacy in adult albino rats.

Method: Evaluation was conducted 3 weeks after a single bilateral intratesticular injection of calcium chloride (CaCl₂) at the dose of 5, 10, 15 or 20 mg per testis per 100 g body weight.

Results: The significant graded diminution in relative sex organ weights, testicular androgenic enzymes like $\Delta^5,3\beta$ -hydroxysteroid dehydrogenase ($\Delta^5,3\beta$ -HSD) and 17 β -hydroxysteroid dehydrogenase (17 β -HSD), glutathione peroxidase (GPx), glutathione S-transferase (GST) and superoxide dismutase (SOD) activities, testicular content of reduced glutathione (GSH), plasma and intratesticular concentrations of testosterone, epididymal sperm count as well as significant elevation in plasma concentrations of luteinizing hormone (LH), follicle-stimulating hormone (FSH) and testicular content of malondialdehyde (MDA) were noted in all the treated groups with respect to vehicle control. There was no chronic general stress in experimental animals as indicated by insignificant changes in plasma concentrations of corticosterone, prolactin, total protein, blood urea nitrogen and fasting blood sugar level. Dose-dependent responses on testicular histopathology were recorded by noting multinucleated giant cells in seminiferous tubules, derangement of tubular architecture along with infiltration of leucocytes and appearance of fibrous tissue throughout the testicular sections. The fertility efficacy of the 10, 15 or 20 mg CaCl₂-treated males was nil, proven after mating with fertile, virgin healthy females, as there were no implantation sites in each uterine horns noted by laparotomy.

Conclusion: Intratesticular CaCl₂ injection at a specific dose might serve as a way of sterilization and may be considered as an alternative to surgical castration in male animals.

© 2006 Elsevier Inc. All rights reserved.

Keywords: Rat; Sterilization; Calcium chloride; Androgenic key enzymes; Gonadotrophins; Testosterone; Fertility; Oxidative stress

1. Introduction

Presently, veterinarians are practicing the surgical method of castration by open surgery, which is the only means of sterilization for male animals. However, castration by open surgery requires postoperative care to minimize the risk of hemorrhage and infection. This method has some disadvantages: it is not cost-effective and time-consuming with risk of postoperative complications. Moreover, this technique is not suited for mass-scale application such as the control of stray dog population. In contrast to the surgical method, the challenge has been taken up by different reproductive biologists to develop a method of chemical sterilization,

which may be a better alternative to surgical castration, as well as suited for mass-scale sterilization of male domestic animals without postoperative hazards. The literature indicates that different workers have evaluated nonsurgical sterilization with injection of various hormones [1–4] in many species of male animals, but these treatments failed to induce permanent sterility. Immunization techniques have also been used to induce antibodies against gonadotrophins and GnRH [5]. The results indicate that such immunization techniques vary in effectiveness and in duration of azospermia. Adverse vaccination reactions are also observed as another disadvantage of this method. Besides the above techniques, researchers have also tried various chemical agents such as cadmium chloride [6], ferric chloride and ferrous sulphate [7], danazol [8], bacillus Calmette–Guérin (BCG) [9], glycerol [10] and lactic acid [11] for chemical castration by intratesticular injection in laboratory and

* Corresponding author. Tel.: +91 033 25568329, +91 09830164986 (residence).

E-mail address: pksamantha_vetpfa@yahoo.com (P.K. Samanta).

domestic animals. All these agents, after intratesticular injection, exhibited pain, pyrexia and even severe inflammation (orchitis). Some agents, e.g., cadmium chloride, glycerol, lactic acid, caused selective destruction of testicular tissue [6,12] with reversible testicular tissue damage [13]. In some cases, the interstitial portion regenerated after an initial phase of testicular atrophy, and this led to secondary male behavior, which caused management problems of the animals [11]. Due to the above complications caused by the use of the aforementioned chemicals, an effective chemosterilizing agent is yet to be established. Very recently, an attempt has been made to induce sterilization by intratesticular calcium chloride (CaCl_2) injection in male adult stray dogs [14] and scrub bulls [15], but the mechanism of action of this chemical agent is still to be explored. Very recently, we have reported that single bilateral intratesticular injection of CaCl_2 resulted in chemosterilization through the generation of free radicals as well as without induction of any general stress response in male Black Bengal goats [16]. A scientific approach has been taken in this experiment to determine the effective dose of CaCl_2 for induction of chemosterilization in rat and to delineate the possible mechanism of action of this agent for induction of such sterilization.

2. Materials and methods

2.1. Animals

Sixty adult male albino rats of Wistar strain, 90 days of age, weighing 130 ± 10 g, were selected and housed four per cage at ambient temperature ($22 \pm 2^\circ\text{C}$) and humidity ($60 \pm 5\%$) in a photoperiod controlled room (light/dark: 14:10 h) with free access to standard laboratory food (formulated in our laboratory) and water ad libitum. The animals were allowed to acclimatize to the laboratory conditions by keeping them for 15 days prior to the experimentation. The *NIH Guide for the Care and Use of Laboratory Animals* [17] was followed throughout the experimental duration. The experimental protocol also met the *Guidelines for Care and Use of Animals in Scientific Research* [18] and was duly approved by the Animal Ethics Committee of the Institute. The body weight of each animal was recorded at the starting day of experiment.

2.2. Experimental design

In order to determine the efficacy of a single intratesticular injection of CaCl_2 for chemosterilization, 48 rats were treated with sterile analytical grade CaCl_2 ($\text{CaCl}_2 \cdot 2\text{H}_2\text{O}$; E. Merck, Mumbai, India) and divided into four groups equally. Twelve rats of each group were given a single bilateral intratesticular injection of 5, 10, 15 or 20 mg CaCl_2 or 0.1 mL normal saline per testis per 100 g body weight, respectively. Twelve rats received only sterile 0.1 mL normal saline per testis per 100 g body weight and were considered as vehicle-treated control.

2.2.1. Intratesticular injection of CaCl_2 solutions

Intratesticular injections were carefully performed. All the injections were given under light ether anesthesia by using insulin syringe (single use). The needle was directed from the codoventral aspect of each testis approximately 0.5 cm from the epididymal tail towards the dorsocranial aspect of that testis. The solution was carefully deposited along the entire route by linear infiltration while withdrawing the needle from proximal to distal end. Necessary care was also taken to prevent the seepage of the solution from the injection site.

2.2.2. Collection of blood and reproductive organs

All the animals were sacrificed after 21 days of CaCl_2 or normal saline injections since previous studies showed permanent chemosterilization 3 weeks after injection. Blood samples were collected from the tip of the tail for the measurement of fasting blood sugar level from all groups of animals. The rats were sacrificed under light ether anesthesia, and body weight of individual rat was recorded quickly before organ dissection. Blood samples were collected from the hepatic vein between 8.00 a.m. and 8.30 a.m. from each animal using heparinized syringe (23-gauge needle) very quickly to minimize the effect of stress on the hormonal parameters. Plasma samples were separated by centrifugation, frozen and stored at -20°C until all the samples had been collected for the determination of the concentrations of testosterone, luteinizing hormone (LH), follicle-stimulating hormone (FSH), corticosterone, prolactin and total plasma protein. Plasma concentrations of prolactin and corticosterone are important indicators of stress exposure, and light ether anesthesia is also a stressor, but all the rats of each group were exposed to ether anesthesia, and so all the animals were homogenous in relation to stress induction. The testis and accessory sex organs, i.e., epididymis, prostate and seminal vesicle, were dissected out quickly, washed in 0.9% (w/v) cold normal saline, pat dried and weighed on mono-pan balance. The wet weights of organs are expressed in milligrams per 100 g body weight. In the case of paired organs, the mean weights of both organs are expressed in milligrams per 100 g body weight. One testis from each animal was used for histopathological study, while the other was used for biochemical assay of different biochemical parameters.

2.3. Histopathological study of testes

One testis from each animal was fixed in Bouin's fixative and then dehydrated in graded alcohol followed by embedding in paraffin wax (melting point $55\text{--}58^\circ\text{C}$) in a bath in hypobaric condition. Paraffin blocks were prepared, and serial sections from the middle part from each testis were taken at a thickness of 5 μm using a rotary microtome (Waxwox, Ambala, India). These sections were stained with hematoxylin–eosin. The qualitative study of seminiferous tubules of each animal was done under phase contrast microscope (Axiolab, Carlzeiss, Oberkochen,

Germany) with special reference to histoarchitecture of seminiferous tubules, interstitial space, germ cell arrangement in tubules, etc.

2.4. Epididymal sperm count

Sperm were collected from an equal length of the caudae of the excised epididymis of each rat by flushing the vas deferens with the same suspension medium (10 mL) containing 140 mM NaCl, 0.3 mM KCl, 0.8 mM Na₂HPO₄, 0.2 mM KH₂PO₄ and 1.5 mM D-glucose (pH adjusted to 7.3 by adding 0.1N NaOH) (E. Merck). The collected sample was centrifuged at 100×g for 2 min, and the precipitate was resuspended in 10 mL of fresh suspension medium. A fraction of suspension (100 µL) was mixed with an equal volume of 1% Trypan blue in the same medium, and the numbers of sperm were counted in four chambers of a hemocytometer slide [19]. At this concentration of Trypan blue (0.5%), the dye completely excludes intact sperms, which appear bright and colorless, but is taken up by dead and damaged sperm, which show blue heads [20]. The sperm numbers are expressed per milliliter of suspension.

2.5. Assay of key testicular androgenic enzyme activities

The testicular tissue of each animal was used for studying the activities of $\Delta^5,3\beta$ -hydroxysteroid dehydrogenase ($\Delta^5,3\beta$ -HSD) and 17 β -hydroxysteroid dehydrogenase (17 β -HSD). Testicular $\Delta^5,3\beta$ -HSD activity was assayed spectrophotometrically according to the procedure of Talalay [21]. The activity of testicular 17 β -HSD was measured in an UV spectrophotometer according to the procedure of Jarabak et al. [22]. One unit of enzyme activity for $\Delta^5,3\beta$ -HSD and 17 β -HSD was considered to be the amount causing a change in absorbance of 0.001 per minute at 340 nm.

2.6. Assay of plasma and intratesticular testosterone concentrations

The testis was homogenized in 0.5 mL of water using a Teflon homogenizer that was fitted into a microfuge tube chilled in ice. Each sample was centrifuged at 10000 rpm for 10 min. The supernatant was removed, frozen and stored until the hormone assay [23]. Plasma and intratesticular concentrations of testosterone were measured following the immunoenzymatic method in an ELISA reader (Merck, Japan), according to the standard protocol of the National Institute of Health and Family Welfare (NIHFW, New Delhi, India) [24]. A commercially available kit (IBL, Hamburg, Germany) for the measurement of this hormone was used. Horseradish peroxidase was used as the enzyme-labeled antigen, which competed with unlabelled antigen for binding of antibody sites on the microplates (solid phase). Assays were performed following standardized protocol. Testosterone concentration was calculated from a standard curve of five standards supplied by IBL. The absorbance of the standard and sample was monitored against the blank at 450 nm. The cross-reaction of the testosterone antibody to

dehydrotestosterone is 10%, and intrarun precision had a coefficient of variation of 6.2%. All the samples were included in a single assay. The assay that validated the correctness of the data in our laboratory was 98%.

2.7. Assay of plasma LH, FSH and prolactin concentrations

The LH, FSH and prolactin concentrations in plasma were measured using a double antibody radioimmunoassay (RIA). The plasma concentrations of LH and FSH were measured according to standard methods [25], and the plasma concentrations of prolactin (PRL) were measured following the procedure of Jacobs [26] with reagents supplied by the Rat Pituitary Distribution Programme and National Institute of Diabetes and Digestive Kidney Diseases (NIDDK, Bethesda, MD, USA). Highly purified rat LH (rLH-I-4), rat FSH (rFSH-I-8) and rat prolactin (rPRL-I-6) were iodinated with 1 mCi ¹²⁵I (Bhaba Atomic Research Centre, Mumbai, India) and freshly prepared chloramine T (Sigma, St. Louis, MO, USA) [27]. Goat antirabbit γ -globulin was used as the second antibody (Indo-Medicine, Texas, USA). NIDDK-rLH-RP-3 was used as a standard, and NIDDK-anti-rLH-S-5 was used for the LH assay. The limit of detection of LH was 0.05 ng at 80%. For FSH, NIDDK-rFSH-RP-2 was used as a standard, and NIDDK-anti-rFSH-S-11 was used for the assay. The limit of detection of FSH was 0.04 ng at 98%. NIDDK-rPRL-RP-3 was used as a standard, and NIDDK-anti-rPRL-S-9 was used for the prolactin assay. The least detectable quantity of plasma prolactin was 0.40 ng at 90%. All samples were assayed on the same day to avoid interassay variation. Intra-assay variations of LH and FSH assay were 3.5%, whereas the intra-assay coefficient of variation was 6% for the prolactin assay.

2.8. Assays of testicular glutathione peroxidase, superoxide dismutase and glutathione S-transferase activities

Testicular tissue was homogenized in chilled 100 mmol sodium phosphate buffered saline (pH 7.4) to give a tissue concentration of 10% (w/v) for the measurement of the activities of glutathione peroxidase (GPx), superoxide dismutase (SOD) and glutathione S-transferase (GST). The activity of testicular GPx was determined according to the procedure described by Paglia and Valentine [28]. Glutathione peroxidase present in the sample catalyzes the oxidation of glutathione (GSH) by cumene hydroperoxide, in the presence of glutathione reductase (GSSG-R) and NAD(P)H. The oxidized GSH (GSSG) is immediately converted to the reduced form (GSH) with a concomitant oxidation of NAD(P)H to NADP⁺. The decrease in absorbance of NAD(P)H was measured at 340 nm (extinction coefficient $\epsilon = 6.22 \times 10^{-6} \text{ M}^{-1} \text{ cm}^{-1}$). GPx activity is expressed as nanomoles of NAD(P)H oxidized per minute per milligram of protein. The SOD activity was measured spectrophotometrically according to standard protocol [29]. One unit of SOD activity is defined as the amount of enzyme required to inhibit the rate of 50% NAD(P)H oxidation and expressed as units per milligram of protein. Glutathione S-transferase

Table 1

Effect of intratesticular injection of CaCl₂ on body weight and sex organ somatic indices in male albino rat; mean±SE, n=12

Condition	Body weight (g)		Testicular somatic index (mg/100 g body wt)	Prostato-somatic index (mg/100 g body wt)	Seminal vesiculo-somatic index (mg/100 g body wt)	Epididymal somatic index (mg/100 g body wt)
	Initial	Final				
Control	131 ^a ±9	161 ^a ±4	1310 ^a ±35.15	220 ^a ±15.65	530 ^a ±25.81	390 ^a ±16.26
5 mg/100 g body wt/testis	130 ^a ±8	160 ^a ±3	684 ^b ±26.18	170 ^b ±12.14	310 ^b ±16.50	260 ^b ±12.65
10 mg/100 g body wt/testis	132 ^a ±8	159 ^a ±6	480 ^c ±22.85	130 ^c ±10.15	250 ^c ±20.62	210 ^c ±9.56
15 mg/100 g body wt/testis	131 ^a ±8	160 ^a ±4	210 ^d ±18.38	70 ^d ±9.85	135 ^d ±16.0	145 ^d ±10.12
20 mg/100 g body wt/testis	130 ^a ±10	162 ^a ±4	130 ^c ±9.65	50 ^c ±6.25	50 ^c ±10.0	91 ^c ±8.95

ANOVA followed by multiple two-tail *t*-test. Means in each vertical column with different superscripts (a–e) differ from each other significantly (^{b–d}*p*<.01, ^c*p*<.001, as compared to the respective control).

activity was measured spectrophotometrically [30] using 1-chloro-2,4-dinitrobenzene (CDNB, Sigma) as substrate. The formation of the product of CDNB, *S*-2,4-dinitro-phenyl glutathione, was monitored by measuring the net increase in absorbance at 340 nm against the blank. The enzyme activity was calculated using the extinction coefficient $\epsilon = 9.6 \text{ M}^{-1} \text{ cm}^{-1}$ and expressed as nanomolar of product formed per minute per milligram of protein. The amount of protein present in the tissue was measured by the method of Lowrey et al. [31].

2.9. Estimation of testicular content of malondialdehyde

The testicular tissue was homogenized (10% w/v) in ice-cold phosphate buffer (0.1 M, pH 7.4), and the homogenate was centrifuged at 15,000×*g* at 4°C for 3 min. The supernatant was used for the estimation of MDA. Malondialdehyde (MDA), also known as thiobarbituric acid reactive substances (TBARS), was determined by the reaction of thiobarbituric acid (TBA, Merck, Germany) with MDA, a product formed due to the peroxidation of lipids, according to the method of Ohkawa et al. [32]. The amount of TBARS formed was measured by absorbance at 530 nm (extinction coefficient, $\epsilon = 1.56 \times 10^5 \text{ M}^{-1} \text{ cm}^{-1}$) using an UV spectrophotometer (Hitachi, Tokyo, Japan).

2.10. Quantification of testicular GSH content

A 10% (w/v) homogenate of testicular tissue in 5% (w/v) metaphosphoric acid was centrifuged at 1000×*g* for 30 min at room temperature, and the deproteinized supernatant was used to assay GSH. This was measured by monitoring the absorbance at 412 nm in an UV spectrophotometer, which

reflects the rate of reduction of 5,5-dithiobis-2-nitrobenzoate (DTNB) to 2-nitro-5-thiobenzoate following the standard method of Zakowski and Tappel [33].

2.11. Estimation of plasma concentrations of corticosterone, total protein, blood urea nitrogen and fasting blood sugar

Plasma concentration of corticosterone was measured spectrofluorometrically (F-3010, Hitachi) according to the method of Glic et al. [34] and modified by Silber [35]. Fluorescence was measured at 463 nm (excitation) and 518 nm (emission) of wavelength by setting the instrument at a spectrofluorometric reading of 80, with a standard corticosterone (Sigma) solution having a concentration of 1.6 µg/mL. A minimum 1.6 µg corticosterone/100 mL serum can be measured by this method. The concentration of corticosterone is expressed as microgram per 100 mL of plasma. Total plasma protein concentration was estimated by the standard method of Lowrey et al. [31] and expressed as gram per decaliter. Blood urea nitrogen was measured using the kit supplied by Dr. Reddy's Laboratories (diagnostic division, Hyderabad, India) according to the manufacturer's instructions. Fasting blood sugar concentration was measured by a single touch glucometer (Blood Life Scan, Johnson & Johnson, Milpitas, CA, USA), and the level is expressed as milligram per 100 mL.

2.12. Fertility efficacy test

On the 21st day postinjection period, both the vehicle-treated and CaCl₂-treated rats were allowed to mate with mature, healthy, fertile, virgin and normal cyclical (4-day estrous cycle) female rats. Each male rat was caged with three

Table 2

Effect of intratesticular injection of CaCl₂ on plasma concentrations of corticosterone, prolactin, fasting blood sugar level, blood urea nitrogen, total plasma protein, testicular contents of MDA and reduced GSH in male albino rat; mean±SE, n=12

Condition	Plasma corticosterone (µg/100 mL plasma)	Plasma prolactin (µg/L)	Fasting blood sugar (mg/100 mL)	Blood urea nitrogen (mg/dL)	Total plasma protein (g/dL)	MDA (nM/mg of tissue)	GSH (nM/mg of protein)
5 mg/100 g body wt/testis	31.12 ^a ±0.24	53.78 ^a ±1.03	83.92 ^a ±0.88	15.12 ^a ±0.83	6.1 ^a ±0.1	28.15 ^b ±0.42	35.64 ^b ±3.15
10 mg/100 g body wt/testis	30.67 ^a ±0.18	53.87 ^a ±0.81	84.16 ^a ±0.83	15.04 ^a ±0.62	6.2 ^a ±0.3	35.10 ^c ±0.34	21.35 ^c ±2.24
15 mg/100 g body wt/testis	30.94 ^a ±0.15	54.05 ^a ±0.76	84.21 ^a ±1.24	15.3 ^a ±0.85	6.0 ^a ±0.4	38.45 ^d ±0.46	12.54 ^d ±3.16
20 mg/100 g body wt/testis	31.20 ^a ±0.32	54.18 ^a ±0.64	84.33 ^a ±1.42	15.24 ^a ±0.65	5.9 ^a ±0.2	44.26 ^c ±0.48	7.12 ^c ±1.15

ANOVA followed by multiple two-tail *t*-test. Means in each vertical column with different superscript (a–e) differ from each other significantly. (^a*p*>.05, ^{b–d}*p*<.01, ^c*p*<.001, as compared to the respective control).

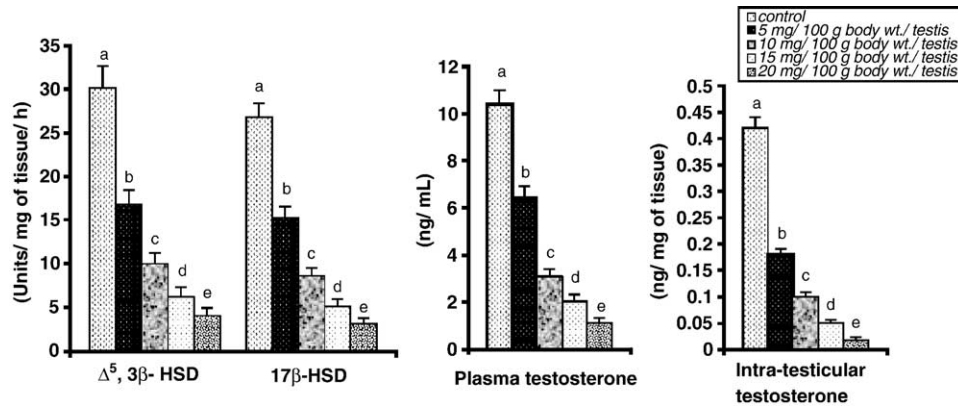


Fig. 1. Testicular androgenic key enzyme activities and plasma concentration of testosterone in mature male albino rats 3 weeks after a single intratesticular injection of CaCl₂. Data as mean±SE, n=12, ANOVA followed by multiple two-tail t-test. Different superscripts (a–e) on each bar differ from each other significantly (^{b,c}p<.01 as compared with respective control).

females for 6 consecutive days. Vaginal smears were examined each morning for the presence of sperm, and the mated females were isolated [4]. The sexual behavior was observed and recorded for all vehicle-treated control male rats and CaCl₂-treated male rats when they came in contact with female rats. The behavioral sequences included noising, genital sniffing, chasing, grasping, mounting, resting, eating or drinking, and aggression [10]. All mated females were kept individually caged and after 10 days; implantation sites were counted in each female by laparotomy [10].

2.13. Statistical analysis

For statistical analysis of our data, ANOVA followed by multiple two-tail t-test was used [36]. Differences were considered significant at p<.05, p<.01 and p<.001. The SPSS statistical software package was used.

3. Results

All animals tolerated the intratesticular injections of CaCl₂ and did not suffer from any agitation, fever or marked inflammatory swelling of the testis. There was no

apparent discomfort exhibited by any of the rats, either on recovery from ether anesthesia after the injection or at any point during the course of the experiment. There was no apparent change in food consumption among the three groups of animals throughout the experimental duration. None of the rats injected with CaCl₂ at all doses showed signs of morbidity or mortality during the studies. Postmortem inspection of each treated animal indicated that there was no injury in the cauda epididymis, due to intratesticular injection of this agent.

3.1. Effect on body weight and sex organ somatic index

There was no significant (p>.05) alteration in body weight in all treated groups in comparison to the vehicle control (Tables 1 and 2). Testicular somatic, epididymal somatic, prostatic somatic and seminal vesiculo-somatic indices were decreased significantly (p<.01) in all the CaCl₂-treated groups with respect to control. All these parameters exhibited a greater level of diminution (p<.001) at high dose compared to other dose treatments (Table 1).

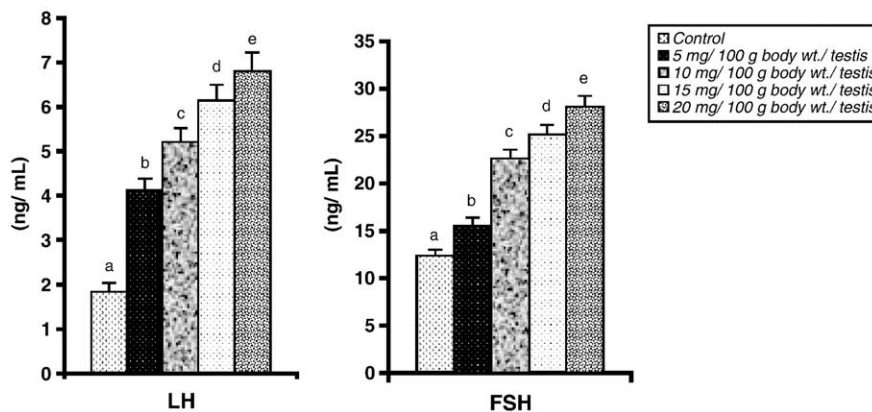


Fig. 2. Plasma concentration of LH and FSH in mature male albino rats 3 weeks after a single intratesticular injection of CaCl₂. Data as mean±SE, n=12, followed by multiple two-tail t-test. Different superscripts (b–e) on each bar differ from each other significantly (^{b,e}p<.01 as compared with respective control).

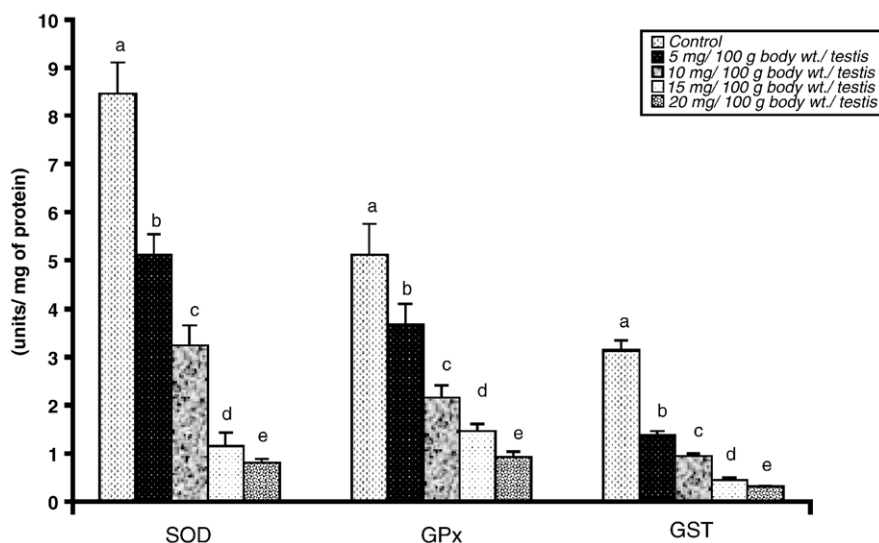


Fig. 3. Testicular activities of SOD, GPx and GST in mature male albino rats 3 weeks after single bilateral intratesticular injection of CaCl_2 . Data as mean \pm SE, $n=12$, followed by multiple two-tail t -test. Different superscripts (a–e) on each bar differ from each other significantly ($^{b,c}p < .01$ as compared with respective control).

3.2. Effect on testicular $\Delta^5,3\beta$ -HSD and 17β -HSD activities

The activities of $\Delta^5,3\beta$ -HSD and 17β -HSD in testicular tissue were decreased significantly ($p < .01$) in all CaCl_2 -treated groups with respect to the vehicle control. Moreover, the 15 mg and 20 mg of CaCl_2 treatments also exhibited a more effective and significant ($p < .001$) inhibition on these parameters compared to the 5 mg or 10 mg of CaCl_2 treatments (Fig. 1).

3.3. Changes in plasma and intratesticular concentrations of testosterone and plasma concentrations of corticosterone and prolactin

A significant ($p < .01$) diminution in plasma and intratesticular concentrations of testosterone was noted in all CaCl_2 -treated groups in comparison to the vehicle control. Remarkably low concentrations of testosterone ($p < .001$) were noted for the 15 mg and 20 mg of CaCl_2 treatments. There were no significant ($p > .05$) changes in plasma

concentrations of corticosterone and prolactin in all treated groups with respect to the vehicle control as well as among the four treated groups (Fig. 1, Table 2).

3.4. Effect on plasma LH and FSH concentrations

Intratesticular injections of 5, 10, 15 and 20 mg of CaCl_2 led to a significant graded elevation ($p < .01$) in the concentrations of plasma LH and FSH in comparison to the vehicle-treated control. The level in these hormone concentrations became more elevated ($p < .001$) with the 15 and 20 mg of CaCl_2 treatment (Fig. 2).

3.5. Effect on testicular SOD, GPx and GST activities

A dose-related decrease was associated with testicular SOD, GPx and GST activities. The activity of these antioxidant enzymes was diminished ($p < .01$) with all the CaCl_2 treatments with respect to the control. The doses of 15 mg and 20 mg caused a greater degree of inhibition ($p < .001$) in the activity of these enzymes (Fig. 3).

Table 3

Fertility performance and epididymal sperm count in mature male albino rats 3 weeks after single bilateral intratesticular CaCl_2 injection

Condition	No. of males mated/co-caged	No. of sperm/microscopic field of vaginal smears, magnification $\times 100$ (mean)	No. of females mated/pregnant	No. of implantation sites/uterine horn (mean)	Epididymal sperm count (no./mL)
Females mated with vehicle-treated control male (6)*	6/6	24	6/5	4.5	11400 ^a \pm 420.10
Females mated with 5 mg CaCl_2 -treated male (6)*	3/6	10	3/1	2.0	2240 ^b \pm 110.40
Females mated with 10 mg CaCl_2 -treated male (6)*	2/6	4.5	2/0	0.0	830 ^c \pm 60.25
Females mated with 15 mg CaCl_2 -treated male (6)*	1/6	3.0	1/0	0.0	450 ^d \pm 52.10
Females mated with 20 mg CaCl_2 -treated male (6)*	1/6	2.0	1/0	0.0	210 ^e \pm 45.20

Laparotomy was performed 10 days after mating.

Means with different superscripts are significantly different ($p < .001$, $n=12$).

* No. of males used for mating purposes.

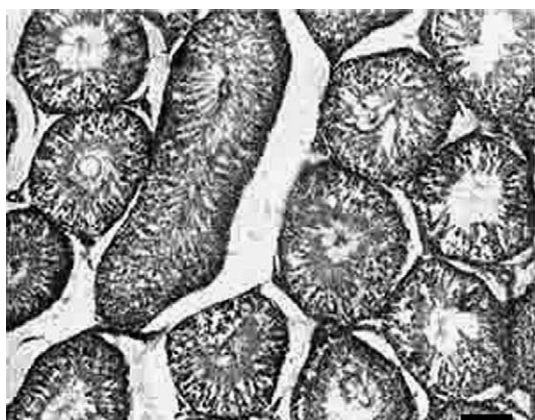

Fig. 4. Testicular cross section of control rat showing normal arrangement of germ cells in seminiferous tubule. Bar=100 μ m.

3.6. Testicular content of MDA

The testicular content of MDA was elevated ($p < .01$) after treatment with 5, 10 or 15 mg of CaCl_2 with respect to the controls, but the 20-mg dose exerted the greatest degree of elevation ($p < .001$) in the testicular content of MDA when compared to the control (Table 2).

3.7. Testicular content of reduced GSH

The testicular content of GSH was decreased ($p < .01$) in a graded manner in response to CaCl_2 treatment for each of the doses with respect to the control (Table 2).

3.8. Effect on epididymal sperm count

The epididymal sperm count was decreased significantly ($p < .01$) in all the CaCl_2 -treated rats in comparison to vehicle-treated control animals. Diminution in the numbers of epididymal sperm after 15 mg or 20 mg of CaCl_2 treatment was more drastic ($p < .001$) with respect to the other dose treatments (Table 3).

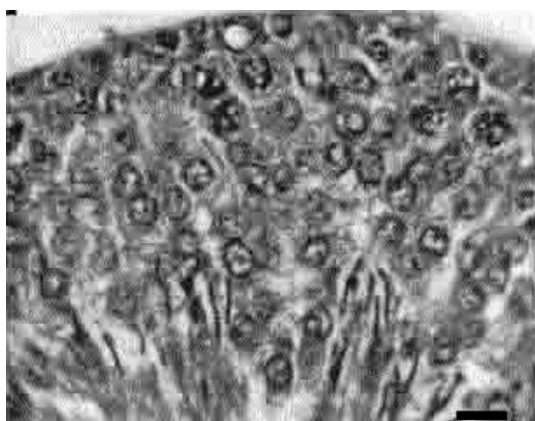


Fig. 5. Testicular cross section of control rat showing normal arrangement of germ cells in seminiferous tubule. Bar=10 μ m.

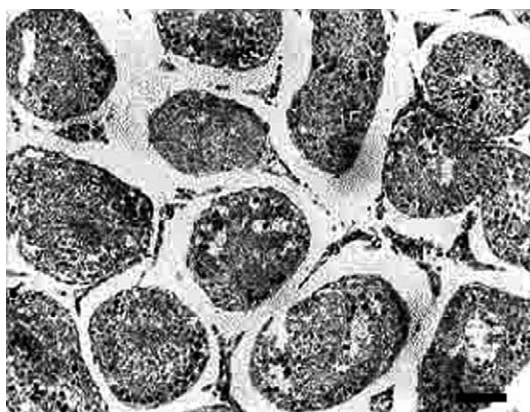


Fig. 6. Testicular cross section of intratesticular injection of 5 mg CaCl_2 -treated rat showing degenerative and coagulate germ cells with presence of multinucleated giant cells into seminiferous tubules. Bar=100 μ m.

3.9. Fasting blood sugar level, blood urea nitrogen and total plasma protein concentrations

No significant ($p > .05$) alteration in fasting blood sugar level, blood urea nitrogen and total plasma protein concentrations was observed in all treated groups with respect to the control as well as among the four treated groups (Table 2).

3.10. Effect on histopathology of testis

Testicular sections showed normal arrangements of germ cells in seminiferous tubules with distinct peritubular space and interstitial cells of Leydig in the control group (Figs. 4 and 5). Calcium chloride treatment at the dose of 5 mg exhibited degeneration of germ cells along with the appearance of some multinucleated giant cells in the seminiferous tubules. Sloughing of immature germ cells from the basement membrane along with the presence of shed cells in the intraluminal space was noted. Exfoliation of germ cells along with the presence of vacuoles in the tubules was observed (Figs. 6 and 7). Intratesticular

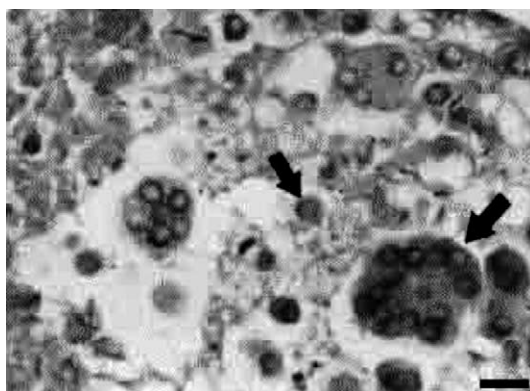


Fig. 7. Testicular cross section of intratesticular injection of 5 mg CaCl_2 -treated rat showing multinucleated giant cells in tubules and detachment of immature germ cells from basement membrane. (Arrows indicate the multinucleated giant cell in seminiferous tubule along with immature germ cell detachment from basement membrane.) Bar=10 μ m.

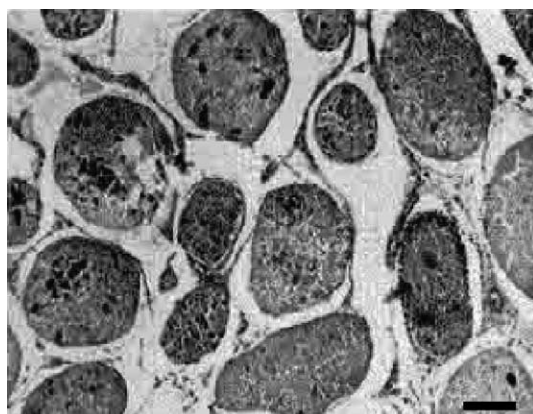


Fig. 8. Testicular cross section of intratesticular injection of 10 mg CaCl_2 -treated rat showing high degree of coagulative necrosis along with appearance of some degenerated giant cells in fibrosed seminiferous tubules along with fibrous tissue in peritubular space. Bar=100 μm .

injection of 10 mg CaCl_2 solution resulted in a remarkable degree of coagulative necrosis along with fibrosis in the seminiferous tubules. Some degenerated giant cells were also evident in the fibrosed seminiferous tubules (Fig. 8). Intratesticular injection of CaCl_2 at the dose of 15 mg resulted in drastic necrosis of testicular parenchyma along with the appearance of vacuolated and atrophied tubules. Most of the tubules were totally distorted, as there was no concrete demarcation between the tubular and extratubular zone. Prominent degeneration into the interstitial Leydig cells with fibrosis was evident with this dose treatment (Fig. 9). At the highest dose (20 mg) of intratesticular injection of CaCl_2 solution, complete derangement of tubular architecture without any distinct boundary between the tubular and extratubular compartment along with infiltration of a large number of leucocytes throughout the testicular tissue was noted. Notable appearance of fibrous

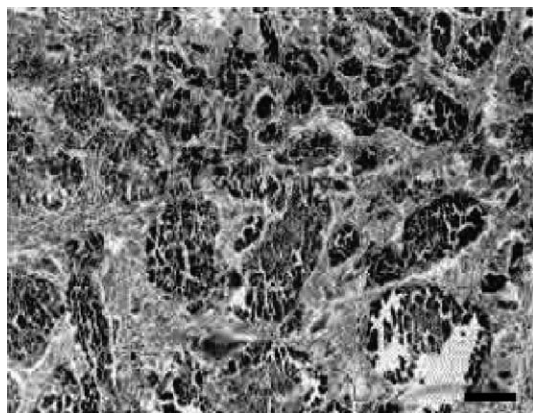


Fig. 9. Testicular cross section of intratesticular injection of 15 mg CaCl_2 -treated rat showing high degree of coagulative necrosis along with coagulate and degenerated germ cells in to the tubules. Most of the seminiferous tubular architecture is completely deranged, atrophied and vacuolated. The presence of fibrous tissue in tubular and peritubular space is also evident. Bar=100 μm .

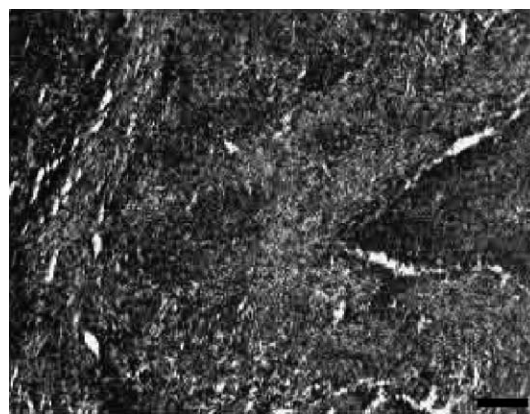


Fig. 10. Testicular cross section of intratesticular injection of 20 mg CaCl_2 -treated rat showing complete derangement of seminiferous tubular architecture and infiltration of leucocytes along with the presence of fibrous tissue throughout the tubular and extratubular zone. Bar=100 μm .

tissue was also noted throughout the testicular sections (Figs. 10 and 11).

3.11. Sexual behavior

There were drastic changes noted in the sexual behavior of the CaCl_2 -treated rats in comparison to the vehicle-treated control rats. Most of the treated rats' appearance and behavior were asexual.

3.12. Fertility performance

Vaginal smears taken from the females after mating with control males showed a large number of sperm in each microscopic field. On the 10th postcoital day, laparotomy showed a notable number of implantation sites in each uterine horn of the female rats (Table 3).

Vaginal smears collected from females after mating with the 5 mg CaCl_2 -treated male rats showed very few sperm in each field. In this case, laparotomy showed a nominal number of implantation sites in each uterine horn of each female rat (Table 3).

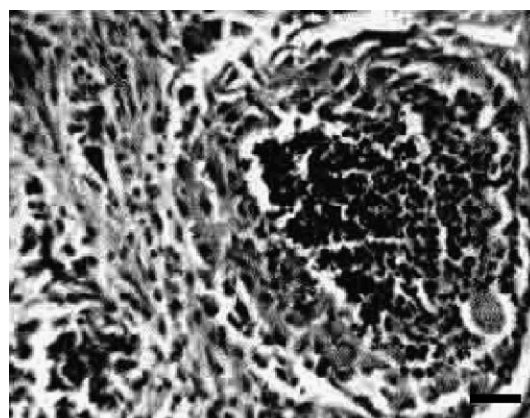


Fig. 11. Testicular cross section of intratesticular injection of 20 mg CaCl_2 -treated rat showing complete derangement of seminiferous tubular architecture and infiltration of leucocytes along with the presence of fibrous tissue throughout the tubular and extratubular zone. Bar=25 μm .

Vaginal smears collected from females after mating with the 10, 15 or 20 mg CaCl₂-treated male rats showed a rare number of sperm in each field. Laparotomy showed no implantation sites in the cases (Table 3).

4. Discussion

This study focused on the dose-dependent CaCl₂-induced chemosterilization in male albino rats. Calcium chloride induced extensive necrosis of the entire testicular tissue, which is in agreement with previous studies of this chemical agent on testis in other domestic animals [14,15]. Testicular histology showed progressive degenerative changes with the graded doses of intratesticular CaCl₂ injection. These changes may be due to the necrotizing properties of CaCl₂, which has been strongly supported by other studies [37]. Besides the necrotizing changes in the seminiferous tubules, germ cell degeneration by CaCl₂ may be due to low concentration of testosterone, as testosterone is the prime regulator for the maintenance of structural morphology as well as physiology of the seminiferous tubule [38]. Induction of testicular degeneration by this chemical agent is supported by the low testicular somatic index in treated rats, as this is an accepted measure of testicular damage [39]. This agent, which causes inhibition in the concentration of testosterone, is supported by the diminution in the activities of testicular $\Delta^5,3\beta$ -HSD and 17β -HSD in a dose-dependent fashion, as these are the key enzymes for testicular androgenesis [40]. This prediction for low plasma concentration of testosterone in CaCl₂-treated rats is consistent with our results when plasma testosterone concentration has been decreased in treated rats in a dose-dependent manner. Degenerative changes were also observed in the interstitial Leydig cells. Such changes lead to a reduction in testosterone concentration [38]. The direct inhibitory effect of CaCl₂ on testosterone synthesis in testis has been further indicated by the present study by a significant elevation in plasma concentration of LH and FSH in the treated animals which may be due to withdrawal of the negative feedback effect of testosterone on the hypothalamo-pituitary axis [41].

The degeneration of germ cells in the CaCl₂-treated testis is possibly mediated by apoptosis. This is supported by the appearance of some multinucleated giant cells in the seminiferous tubules, as it is an important feature of germ cell apoptosis [42,43]. Apoptosis of testicular germ cells by CaCl₂ treatment is further supported by the sloughing of immature germ cells (shed cells) in the intraluminal space [42]. Moreover, the appearance of exfoliated germ cells in the seminiferous epithelium is also an indication that germ cells are undergoing apoptosis, which is consistent with other findings [43]. Germ cell detachment from the basal lamina also indicates the induction of apoptosis in testicular tissue, which is supported by others [42,44]. Apoptosis of germ cells in the testis is possibly due to the low concentration of testosterone, as testosterone is a cell survival factor for germ

cells in the testis, and withdrawal of testosterone induces apoptosis in testicular germ cells [45]. Reduced concentration of intratesticular testosterone activates testicular caspase-3 activity, which is associated with germ cell apoptosis [46]. Moreover, the apoptotic property of CaCl₂ through the induction of caspase-3 activity was also reported by others [47]. It is important to note that necrosis and apoptosis can occur simultaneously [48], and, after that, apoptotic cells undergo secondary necrosis [49].

Another way in which testicular degeneration was noted by CaCl₂ may be through the generation of reactive oxygen species (ROS) or their products in testicular tissue, as ROS production in the testis results in a low level of testosterone, which is associated with germ cell degeneration [50,51]. Calcium chloride is also an effective chemical agent for inducing the generation of ROS in tissues [52]. This is supported by the appearance of giant cells in seminiferous tubules in the treated group, and these giant cells are also actively engaged in free radical production [53]. Calcium chloride-induced testicular oxidative stress can be assessed by the measurement of MDA [54]. The fact that an intratesticular injection of CaCl₂ was associated with free-radical production in the testis was reflected by the high testicular content of MDA. Free-radical production in the testis of treated rats is supported by the infiltration of leucocytes in the seminiferous tubules, as testicular free-radical production is closely associated with leucocyte infiltration [55].

This elevation in the formation of free radicals in the testes treated with CaCl₂ is also supported by the diminution in testicular GPx, SOD and GST activities, as these are considered important scavenging enzymes against free radicals in male gonads [56,57]. Besides these enzymatic antioxidants, CaCl₂ treatment was also associated with a low content of testicular reduced GSH, an important nonenzymatic antioxidant in the testis [58]. The low activities of testicular GPx, SOD and GST along with a low content of GSH among the treated rats may be due to the low concentrations of testosterone [50,51] or the direct effect of CaCl₂, which is not explored properly in this study. It may be assumed that testicular degeneration in this experiment was due to generation of free radicals in the testis, as free radicals are inhibitors for spermatogenesis [19] and testicular androgenesis [59]. In addition, the reduced levels of GST activity and GSH content in the testes would be another cause for the degenerative necrosis of seminiferous tubules. Glutathione S-transferase and GSH are important regulators for proliferation and differentiation of germ cells and provide protection to germ cells against the harmful effects of free radicals [60]. However, Bauche et al. [61] showed that Sertoli and peritubular cells have a high content of GSH and a higher activity of GST. Degeneration of these cells by CaCl₂ treatment could be a possible cause for the lower content of GSH and GST activity in the treated testis.

Rapid production of ROS results in DNA fragmentation, protein degradation that may lead to germ cell

apoptosis [57]. Besides this, improper functioning or diminution in the activities of GPx, GST, SOD and content of GSH in testis may also lead to germ cell apoptosis, as these enzymes act as an anti-apoptotic factor [57,62–64]. In CaCl₂-treated rats, the diminution in prostatic, seminal vesiculo-somatic and epididymal somatic indices may be due to low plasma concentration of testosterone, as growth of these accessory sex organs is solely controlled by testosterone [65]. Moreover, the low plasma concentration of testosterone in CaCl₂-treated rats has been further indicated here by significant diminution in epididymal sperm count, as sperm maturation in the epididymis is controlled by testosterone [38]. Peritubular space in testicular sections of CaCl₂-treated rats also exhibited significant degenerative changes along with proliferation of fibrous tissue. Such changes may be due to the low level of plasma testosterone [66]. Moreover, fibrosis of peritubular space in treated animals is also consistent with previous studies on other chemical agents [6,12]. The infiltration of leucocytes into the tubular and peritubular zones is possibly due to the degeneration of germ cells, which may release a large amount of proteins that diffuse out to the luminal cavity of the seminiferous tubule and into the interstitium where they act as antigen to promote chemotaxis of leucocytes [13].

To confirm the induction of successful chemosterilization by single intratesticular injection of CaCl₂, the fertility efficacy test was performed in the present study. A significant diminution in this parameter was noted after mating the low dose-treated group with mature, healthy, virgin and fertile females. In contrast, there was no implantation site in females after mating with the 10, 15 or 20 mg CaCl₂-treated animals. This is due to the lack of a minimum requisite number of motile and fertile sperm in treated males [67]. Drastic alterations in the sexual behavior of the treated males were observed in the present study with the loss of libido. These alterations may be due to the significant diminution in the concentration of testosterone, as testosterone is the prime regulator of the male sexual behavior [10].

Whether this chemical agent is associated with any chronic stress response, we measured the stress indicators, such as plasma levels of corticosterone, prolactin, total protein, blood urea nitrogen and fasting blood sugar level [68]. Almost any type of stress will cause an increase in the secretion of corticosterone in rat [69]. Stress also induces secretion of prolactin from the adeno-hypophysis [70]. As there was no significant alteration in plasma corticosterone, prolactin, total protein, blood urea nitrogen and fasting blood sugar level in treated groups with respect to control, it may be stated that this chemosterilization is not associated with any chronic stress response in general. Since both the control and the CaCl₂-treated animals were sacrificed under light anesthesia, the stress of anesthesia was similar in both cases, and in this respect the rats were homogeneous in relation to the stress of anesthesia.

It is concluded that intratesticular CaCl₂ injection may be considered a chemosterilizing agent. It results in infertility by

germ cell apoptosis through direct necrotizing effect or by the generation of ROS in the testis. The pathway to infertility is not clear from the present study, and it should be explored in the future. This agent may be used as a sterilizing agent for the control of the population of undesirable mammals, like stray dogs, after further investigation.

Acknowledgments

The authors are deeply grateful to Prof. D.N. Jana (Registrar), Prof. M.K. Bhowmik (Director of Research, Extension and Farms) and Prof. D.K. Dey (Head, Department of Surgery and Radiology, West Bengal University of Animal and Fishery Sciences, Calcutta) for their interest in this study.

References

- [1] Kerr JB, Sharpe RM. Effects and interaction of LH and LHRH agonist on testicular morphology and function in hypophysectomized rats. *J Reprod Fertil* 1986;76:175–92.
- [2] Dube D, Assaf A, Pelletier G. Morphological study of the effects of a GnRH agonist on the canine testis after 4 months of treatment and recovery. *Acta Endocrinol (Copenh)* 1987;116:413–7.
- [3] Matsumoto AM. Is high dosage of testosterone an effective male contraceptive agent? *Fertil Steril* 1988;50:324–8.
- [4] Dhar JD, Setty BS. Effect of a nonsteroidal antiandrogen, anandron, on the reproductive system and fertility in male rats. *Contraception* 1990;42:121–38.
- [5] Gonzalez A, Allen AF, Post AK. Immunological approaches to contraception in dogs. *J Reprod Fertil Suppl* 1989;39:189–98.
- [6] Parizek J. Sterilization of the male by cadmium salts. *J Reprod Fertil* 1960;1:294–309.
- [7] Kar AB, Kamboj VP, Goswami A. Sterilization of male rhesus monkeys by iron salts. *J Reprod Fertil* 1965;9:115–7.
- [8] Dixit VP, Lohiya NK, Arya M, Argrawal M. Chemical sterilization of male dogs after a single testicular injection of 'Danazol'. *Folia Biol* 1973;23:305–10.
- [9] Naz RK, Talwar GP. Immunological sterilization of male dogs by BCG. *Int J Androl* 1981;4:111–28.
- [10] Wiebe JP, Barr KJ. The control of male fertility by 1,2,3-trihydroxypropan (THP; glycerol): rapid arrest of spermatogenesis without altering libido, accessory organs, gonadal steroidogenesis and serum testosterone, LH and FSH. *Contraception* 1984;29:291–302.
- [11] Fordyce G, Hodge PB, Beaman NJ, Leing AR, Campero C, Shepherd RK. An evaluation of calf castration by intratesticular injection of a lactic acid solution. *Aust Vet J* 1989;66:272–6.
- [12] Immegart HM, Threlfall WR. Evaluation of intratesticular injection of glycerol for nonsurgical sterilization of dogs. *Am J Vet Res* 2000;61:544–9.
- [13] Heath E, Arowolo R. The early histopathologic effects of intratesticular injection with hyperosmolar glycerol, glucose or NaCl solutions. *Andrologia* 1987;19:654–61.
- [14] Samanta PK. Chemosterilization of stray dogs. *Ind J Anim Health* 1988;37:61–2.
- [15] Mitra B, Samanta PK. Testicular degeneration of scrub bulls by calcium chloride. *Ind J Vet Surg* 2000;21:37–8.
- [16] Jana K, Ghosh D, Samanta PK. Evaluation of single intratesticular injection of calcium chloride for non-surgical sterilization of male Black Bengal goats (*Capra hircus*): a dose dependent study. *Anim Reprod Sci* 2005;86:89–108.
- [17] Guide for the care and use of laboratory animals. NIH Publication No. 85-23. Bethesda (Md): US Department of Health and Human Services, National Institute of Health; 1985 [revised].

- [18] Guidelines for care and use of animals in scientific research. New Delhi (India): Indian National Science Academy; 1992 [revised 2000].
- [19] Alvarez JG, Story BT. Assessment of cell damage caused by spontaneous lipid peroxidation in rabbit spermatozoa. *Biol Reprod* 1984;30:323–31.
- [20] Samanta L, Chainy GBN. Comparison of hexachloro-cyclohexane induced oxidative stress in the testis of immature and adult rats. *Comp Biochem Physiol* 1997;118C:319–27.
- [21] Talalay P. Hydroxysteroid dehydrogenase. In: Colowick SP, Kaplan NO, editors. *Methods in enzymology*. New York: Academic Press; 1962. p. 512–6.
- [22] Jarabak J, Adams JA, Williams-Ashman HG, Talalay P. Purification of a 17 β -hydroxysteroid dehydrogenase of human placenta and studies on its transhydrogenase function. *J Biol Chem* 1962;237:345–357.
- [23] Tohda A, Matsumiya K, Tadokoro Y, et al. Testosterone suppresses spermatogenesis in juvenile spermatogonial depletion (*jsd*) mice. *Biol Reprod* 2001;65:532–7.
- [24] Srivastava TG. Enzyme linked immunosorbant assay for steroid hormones. In: Misro MM, editor. *Orientation training course on research methodology in reproductive biomedicine*. New Delhi: National Institute of Health and Family Welfare (NIHFW); 2002. p. 55–8.
- [25] Moudgal NR, Madhwa Raj HG. Pituitary gonadotrophins. In: Jaffe BM, Behrman HR, editors. *Methods of hormone radioimmunoassay*. New York: Academic Press; 1974. p. 67–85.
- [26] Jacobs LS. Prolactin. In: Jaffe BM, Behrman HR, editors. *Methods of hormone radioimmunoassay*. New York: Academic Press; 1979. p. 199–222.
- [27] Greenwood FO, Hunter WM, Glover JS. The preparation of ¹³¹I-labeled human growth hormone of high specific activity. *Biochem J* 1963;89:114–23.
- [28] Paglia DE, Valentine WN. Studies on quantitative and qualitative characterization of erythrocyte glutathione peroxidase. *J Lab Clin Med* 1967;70:158–69.
- [29] Paoletti F, Macoli A. Determination of superoxide dismutase activity by purely chemical system based on NAD(P)H oxidation. In: Packer L, Glazer AN, editors. *Methods in enzymology*, vol. 186. New York: Academic Press; 1990. p. 209–20.
- [30] Habig WH, Pabst MJ, Jocoby WB. Glutathione S-transferase: the first step in mercapturic acid formation. *J Biol Chem* 1974;249:7130–9.
- [31] Lowrey OH, Resebrough NJ, Farr AL, Randal J. Protein measurement with Folin-phenol reagent. *J Biol Chem* 1951;193:265–75.
- [32] Ohkawa H, Ohishi N, Yagi K. Assay for lipid peroxides in animal tissues by thiobarbituric acid reaction. *Anal Biochem* 1979;95:351–8.
- [33] Zakowski JJ, Tappel AL. A semi-automated system for measurement of glutathione in the assay of glutathione peroxidase. *Anal Biochem* 1978;89:430–6.
- [34] Glic D, Dorothy Van R, Lavine S. Fluorometric determination of corticosterone and cortisol in 0.02–0.05 milliliters or sub-milligram samples of adrenal tissue. *Endocrinology* 1964;74:653–7.
- [35] Silber RH. Fluorometric analysis of corticoids. In: Glic D, editor. *Methods in biochemical analysis*. New York: Interscience Publishers; 1966. p. 63.
- [36] Das D. Analysis of variance. In: Das D, Das A, editors. *Statistics in biology and psychology*. Calcutta: Academic Publishers; 1998. p. 250–82.
- [37] Albers GW, Theilen GH. Calcium chloride for treatment of subcutaneous lipomas in dogs. *J Am Vet Med Assoc* 1985;186:492–4.
- [38] Sharpe RM, Maddocks S, Millar M, Saunders PTK, Kerr JB, McKinnell C. Testosterone and spermatogenesis: identification of stage dependent, androgen-regulated proteins secreted by adult rat seminiferous tubules. *J Androl* 1992;13:172–84.
- [39] Foote RH, Schermerhorn EC, Simikili ME. Measurement of semen quality, fertility and reproductive hormones to assess dibromochloropropane (DBCP) effects in live rabbits. *Fundam Appl Toxicol* 1986;6:628–37.
- [40] Ghosh D, Chowdhury A, Biswas NM, Ghosh PK. Effect of lithium chloride on testicular steroidogenesis and gametogenic functions in male albino rats. *Life Sci* 1990;46:127–37.
- [41] Tillbrook AJ, Clarke IJ. Negative feedback regulation of the secretion and actions of gonadotrophin releasing hormone in males. *Biol Reprod* 2001;64:735–42.
- [42] Doerksen T, Bonoit G, Trasler JM. Deoxyribonucleic acid hypomethylation of male germ cells by mitotic and meiotic exposure to 5-azacytidine is associated with altered testicular histology. *Endocrinology* 2000;141:3235–44.
- [43] Xu C, Lu MG, Feng JS, Guo QS, Wang XF. Germ cell apoptosis induced by *Ureaplasma urealyticum* infection. *Asian J Androl* 2001;3:199–204.
- [44] Blanco-Rodriguez J, Martinez-Garcia C. Apoptosis precedes detachment of germ cells from the seminiferous epithelium after hormonal suppression by short-term oestradiol treatment of rats. *Int J Androl* 1998;21:109–15.
- [45] Young KA, Nelson RJ. Mediation of seasonal testicular regression by apoptosis. *Reproduction* 2001;122:677–85.
- [46] Kim JM, Ghosh SR, Weil ACP, Zirkin BR. Caspase-3 and caspase-activated deoxyribonuclease are associated with testicular germ cell apoptosis resulting from reduced intratesticular testosterone. *Endocrinology* 2001;142:3809–16.
- [47] Juin P, Pelletier M, Oliver L, et al. Induction of caspase-3 like activity by calcium in normal cytosolic extracts triggers nuclear apoptosis in a cell free system. *J Biol Chem* 1998;273:17559–64.
- [48] Robertson JD, Orrenius S. Molecular mechanism of apoptosis induced by cytotoxic chemicals. *Crit Rev Toxicol* 2000;30:609–27.
- [49] Honda O, Kuroda M, Joja I, Asaumi J, Takeda A, Akaki S. Assessment of secondary necrosis of jerked cells using a new microscopic system and double staining method with annexin V and propidium iodide. *Int J Oncol* 2000;16:283–8.
- [50] Peltola V, Huhtaniemi I, Metsa-ketla T, Ahotupa M. Induction of lipid peroxidation during steroidogenesis in rat testis. *Endocrinology* 1996;137:105–12.
- [51] Chainy GBN, Samantaray S, Samanta L. Testosterone induced changes in testicular antioxidant system. *Andrologia* 1997;29:343–50.
- [52] Kakkar P, Mehrotra S, Viswanthan PN. Interrelation of active oxygen species, membrane damage and altered calcium functions. *Mol Cell Biochem* 1992;111:11–5.
- [53] St Clair DK, Oberley TD, Muse KE, St Clair WH. Expression of manganese superoxide dismutase promotes cellular differentiation. *Free Radic Biol Med* 1994;16:275–82.
- [54] Gutteridge JMC. Lipid peroxidation and antioxidants as biomarkers of tissue damage. *Clin Chem* 1995;41:1819–28.
- [55] Sikka SC. Relative impact of oxidative stress on male reproductive function. *Curr Med Chem* 2001;8:851–62.
- [56] Samanta L, Roy A, Chainy GBN. Changes in rat testicular antioxidant defense profile as a function of age and its impairment by hexachlorocyclohexane during critical stages of maturation. *Andrologia* 1999;31:83–90.
- [57] Rao AVSK, Shaha C. Role of glutathione S-transferase in oxidative stress-induced male germ cell apoptosis. *Free Radic Biol Med* 2000;29:1015–27.
- [58] Grosshans K, Calvin HI. Estimation of glutathione in purified populations of mouse testis germ cells. *Biol Reprod* 1985;33:1197–205.
- [59] Georgiou M, Parkins LM, Payne AH. Steroid synthesis-dependent, oxygen-mediated damage of mitochondrial and microsomal cytochrome P-450 enzymes in rat Leydig cell cultures. *Endocrinology* 1987;121:1390–9.
- [60] Gopalakrishnan B, Shaha C. Inhibition of sperm glutathione S-transferase leads to functional impairment due to membrane damage. *FEBS Lett* 1998;422:296–300.

- [61] Bauche F, Fonchard M, Jegou B. Antioxidant system in rat testicular cells. *FEBS Lett* 1994;349:392–6.
- [62] Chandra J, Samali A, Orrenius S. Triggering and modulation of apoptosis by oxidative stress. *Free Radic Biol Med* 2000;29:323–33.
- [63] Nakagawa Y, Imai H. Noval functions of mitochondrial phospholipid hydroperoxide glutathione peroxidase (OH GPx) as an anti apoptotic factor. *J Health Sci* 2000;46:414–7.
- [64] Kasahara E, Sato EF, Miyoshi M, et al. Role of oxidative stress in germ cell apoptosis induced by di(2-ethylhexyl) phthalate. *Biochem J* 2002;365:849–56.
- [65] Ghosh SP, Chatterjee TK, Ghosh JJ. Synergistic role of prolactin and testosterone in the regulation of acid phosphatase activity and isoenzyme pattern in accessory sex organs of adult male rats. *J Reprod Fertil* 1983;67:235–41.
- [66] Jegou B, Sharpe RM. Paracrine mechanism in testicular control. In: Dekrester D, editor. *Molecular biology of male reproduction*. London: Academic Press; 1993. p. 271–95.
- [67] Grima J, Silvestrini B, Cheng CY. Reversible inhibition of spermatogenesis in rats using a new male contraceptive, 1-(2, 4-dichlorobenzyl)-indole-3-carbohydrazide. *Biol Reprod* 2001;64:1500–8.
- [68] Cohen RDH, King BD, Thomas LR, Janzen ED. Efficacy and stress of chemical versus surgical castration of cattle. *Can J Anim Sci* 1990;70:1063–72.
- [69] Guyton AC, Hall JE, editors. *Textbook of medical physiology*. Philadelphia: WB Saunders; 1996.
- [70] Knigge U, Matzen S, Warberg J. Histaminergic mediation of stress induced release of PRL in male rats. *Neuroendocrinology* 1988;47:68–74.