

Original research article

Sterilization of male stray dogs with a single intratesticular injection of calcium chloride: a dose-dependent study

Kuladip Jana^{a,1}, Prabhat Kumar Samanta^{b,*}

^aDepartment of Veterinary Surgery and Radiology, West Bengal University of Animal and Fishery Sciences, Kolkata, West Bengal 700 078, India

^bInstitute of Animal Health Research and Management, Peoples for Animals, Kolkata, West Bengal 700 078, India

Received 15 December 2005; accepted 2 January 2007

Abstract

Objective: To study a method of chemical sterilization and its efficacy in adult male stray dogs.

Methods: Sterilization was performed 45 days after a single bilateral intratesticular injection of calcium chloride (CaCl₂) at the doses of 5, 10, 15 or 20 mg per testis per kg body weight.

Results: Histomorphological measures of testes showed total necrosis of testicular tissue at 45 days after an injection of either 10 or 15 or 20 mg CaCl₂ along with fibrosis and hyalinization in seminiferous tubules and interstitial spaces. Infiltration of leucocytes was also observed with the 10- or 15-mg dose. Disintegration of germ cell arrangement in seminiferous tubules and washing out of germ cells from the tubules were noted with the 5-mg dose. Relative organ weight, epididymal sperm count, plasma and intratesticular concentrations of testosterone, testicular activities of $\Delta^5,3\beta$ -hydroxysteroid dehydrogenase ($\Delta^5,3\beta$ -HSD), 17β -hydroxysteroid dehydrogenase (17β -HSD), glutathione peroxidase (GPx), glutathione S-transferase (GST) and superoxide dismutase (SOD) and testicular contents of glutathione (GSH) and glutathione disulphide (GSSG) and the ratio of GSH/GSSG, all were declined in each of the calcium chloride treated groups in comparison to the control group. Increases occurred in testicular malondialdehyde (MDA) and plasma concentrations of LH and FSH with each of the treatments by comparison with the control group. Plasma concentrations of cortisol, fasting blood sugar level, blood urea nitrogen as well as packed cell volume (PCV) and total plasma protein were recorded to monitor the changes in chronic stress in the experimental animals. Changes in these parameters were not significant.

Conclusion: An intratesticular injection of CaCl₂ at specified doses could be a suitable method of sterilization in preference to surgical castration of dogs.

© 2007 Elsevier Inc. All rights reserved.

Keywords: Dog; Calcium chloride; Sterilization; Androgenic key enzymes; Antioxidant enzymes; Stress; Testosterone

1. Introduction

Overpopulation of stray dogs found in urban and rural areas in India poses serious problems in the community from a public health point of view, since these stray dogs are primarily responsible for the transmission of deadly diseases like rabies to human beings and animals. The uncontrolled populations of stray dogs are fast increasing in the country. Although sterilization of male and female dogs is ideal for prevention of overpopulation, sterilization of male may be more beneficial, because males have the potential to

produce a greater number of offspring than females. Surgical castration removes the testes from the scrotum via an incision in male animals. This method is effective, but infection or bleeding can become a problem and it is also time consuming, not cost-effective and needs skilled surgeons. Moreover, for large-scale application of this method, especially for controlling the population of undesirable mammals in our community like stray dogs, it is not effective. Besides this, postoperative care and management of the animal are also required to prevent infection [1]. Vasectomies and vasal occlusion are less invasive surgical procedures than castration. Moreover, these procedures carry similar anesthetic risks and post-surgical complications [2,3]. Advantages of nonsurgical chemical sterilization are apparent reduction of pain and stress, and elimination of hemorrhage, hernia, infection,

* Corresponding author. Tel.: +91 033 255 683 29 or +91 098 301 649 86.

E-mail address: pksamanta_vetpfa@yahoo.com (P.K. Samanta).

¹ Present address: Garrison Institute on Aging, Texas Tech University, Health Sciences Center, Lubbock, TX 79430, USA.

myiasis and other surgical sequelae [4]. Actually, scientists with an interest in animal welfare have been attempting to define the criteria that can identify husbandry systems that are less stressful on the physiological and ethological well being of animals [4]. Veterinarians have been practicing surgical methods of castration by open surgery to date, the only means of sterilizing method by compromising various constraints of it, as there is no suitable alternative sterilizing method for male animals.

An ideal chemical sterilizing agent for domestic animals would be one that effectively arrests spermatogenesis and androgenesis as well as libido and absence of toxic and untoward side effects [5]. Otherwise, the development of secondary sex characteristics may cause management problems of the animals in the community, especially if they become dangerous at their breeding season. Such an ideal chemo-sterilizing agent has not been described previously, although many compounds have been studied for the purpose of inhibiting or arresting spermatogenesis. While many other compounds tested possess some anti-spermatogenic or antifertilizing capacity, their cytotoxic, neurotoxic or antimetabolic effects invariably overshadowed their chemo-sterilizing action [5].

For the last few years, researchers have been interested in developing a method for nonsurgical chemo-sterilization, as this process is suitable for mass-scale application and may be a better alternative to surgical castration. Various agents have been used for nonsurgical chemical sterilization of male animals: the injection of steroid hormones including androgens [6], progestagens [7], antiandrogens [8], anabolic steroids [9] and androgens plus progestagens [10] in many species. However, these treatments do not consistently result in sterility. Gonadotrophin-releasing hormone (GnRH) agonists have also been used to induce sterilization [11,12] with better results. However, as the effects of these agents are variable and also not permanent, repeated treatment is often necessary, and these methods are not cost-ineffective or suitable for mass-scale application. Immunization techniques have also been used to induce antibodies against gonadotrophins and GnRH [13,14]. However, the results indicated that such immunization techniques varied in effectiveness and in the duration of azoospermia. Adverse vaccination reactions were also observed as another disadvantage of this method. Researchers have also used various chemical agents including cadmium chloride [15,16], ferric chloride and ferrous sulphate [17], zinc arginine [18], danazol [19], BCG [20], glycerol [21] and lactic acid [22] by intratesticular injection for the same purpose. All these agents cause some pain and pyrexia or even severe inflammation (orchitis) after intratesticular injection. Some agents (e.g., cadmium chloride, glycerol, lactic acid) caused selective destruction of the testicular parenchyma [15,23] with reversible testicular tissue damage [24]. In some cases, the interstitial portion regenerated after an initial phase of testicular atrophy [25] and this led to secondary male behavior, which caused

management problems of the animals [22]. However, all of these treatments failed to achieve the desired result satisfactorily. Due to the above complications following the use of these chemicals, an effective chemo-sterilizing agent has yet to be established.

Recently, we reported that a single bilateral intratesticular injection of CaCl_2 solution resulted in induction of permanent (irreversible) chemo-sterilization in male albino rats and male goats, the germ cell apoptosis, i.e., necrosis along with concomitant production of reactive oxygen species at the testicular level as well as significant diminution in testosterone concentration without imposition of any pain, general stress response, metabolic toxicity or any toxic and untoward side effects [1,26,27]. This simple technique fulfills the criteria of a method for nonsurgical sterilization of male animals.

In continuation of our previous work, in this present study, we investigated the effectiveness of CaCl_2 for chemical castration in male stray dogs to further study the possible mechanism of action of this agent for male sterilization.

2. Materials and methods

2.1. Animals

Clinically healthy male stray dog ($n=30$) weighing 10 to 15 kg, aged from 2 to 3 years with normal libido in the breeding season (September–October), were used in this study, which was approved by the Ethical Committee of the Faculty of Veterinary Surgery and Radiology, West Bengal University of Animal and Fishery Sciences. All the animals were accustomed to the laboratory environment and handling procedures before experimentation. Dogs were seronegative for *Brucella canis* and routinely dewormed and vaccinated prior to arrival in the animal housing area. The animal house had artificial lighting and controlled temperatures (22°C , ranging from 19°C to 25°C). The dogs were housed singly or in pairs in indoor and outdoor runs, fed a standard commercial dog food and given water ad libitum. Investigations were conducted in accordance with the “Principles for the Care and Use of Research Animals” promulgated by the Society for the Study of Reproduction. Guidelines for Ethical Conduct in the Care and Use of Animals (American Psychological Association) were followed throughout the experimental duration. The Animal Ethics Committee of the institute also duly approved the protocol of this experiment.

2.2. Experimental protocol

The maximum effective dose of CaCl_2 for induction of chemo-sterilization was estimated by dividing the 30 animals randomly into five groups. Animals in four groups received a single bilateral intratesticular injection of sterile analytical grade of $\text{CaCl}_2 \cdot 2 \text{H}_2\text{O}$, (Merck, Mumbai, India) at doses of 5, 10, 15 or 20 mg/kg body weight, respectively, given in 1 mL solution containing 1% lignocaine hydro-

chloride (a local anesthetic agent, Astra IDL, Bangalore, India). The animals in the control group received a single bilateral intratesticular injection of 1 mL sterile normal saline which contained 1% lignocaine hydrochloride.

2.3. Intratesticular injection of CaCl_2 solutions

Each intratesticular injection was performed using a sterile 21-gauge needle directed from the codoventral aspect of each testis approximately 1 cm from the epididymal tail and towards the dorsocranial aspect of that testis so that the solution was deposited over the entire route by linear infiltration while withdrawing the needle from the proximal end to the distal end. Necessary care was taken to avoid the seepage of the solution from the injection site. Nothing more was done following an injection. All the dogs were restrained through gentle handling and proper care. The intratesticular injections were given very carefully like any other intramuscular injections. The animals were also restrained through proper handling procedure in prior experiment in the case of vaccination and blood collection, etc. The animals were kept under routine clinical observations.

2.4. Scarification and collection of blood and reproductive organs

From the duration-dependent study, we observed that after a single bilateral intratesticular injection of CaCl_2 at the highest dose in dog, the degeneration of testicular parenchyma was started after 7 days and after 45 days of treatment; total necrosis of the testicular parenchyma was evident and there was no sign of testicular regeneration either. Forty-five days following intratesticular injection, both testes were obtained from all dogs either by castration [28] or removal immediately following euthanasia [29] and wet weights recorded. The right testis from each animal was used for histomorphological studies, while the left one was used for biochemical assays. Blood was collected from a jugular vein of each dog into heparinized tubes before castration in fasted animals during the period 8:00 a.m.–8:30 a.m. These samples were analyzed immediately after collection for packed cell volume (PCV), blood urea nitrogen, total protein and fasting blood sugar level. Samples were also centrifuged for 10 min at $13,000\times g$ for plasma separation then stored at -20°C until assayed for testosterone, LH, FSH and cortisol concentrations.

2.5. Epididymal sperm count

The epididymal sperm counts were performed accordingly as described previously [30]. The live and dead sperm were counted by trypan blue exclusion method in four chambers of a hemocytometer slide [31]. The sperm number was expressed per milliliter of suspension.

2.6. Histopathological studies on the testes

The right testis from each animal was fixed in Bouin's fixative and embedded in paraffin wax. A 5- μm -thick section was cut from the middle portion of each testis,

stained with hematoxylin–eosin and examined under light microscopy at $100\times$ and $400\times$ magnifications. The structures of the seminiferous tubules and interstitial spaces in the testis were examined.

2.7. Assays for plasma and intratesticular testosterone and cortisol concentrations

The testicular tissue was homogenized in 0.5 mL of water using a Teflon homogenizer that was fitted into a microfuge tube chilled in ice. Each sample was centrifuged at 10,000 rpm for 10 min. The supernatant was removed, frozen and stored until hormone assay [32]. The plasma and intratesticular concentrations of testosterone and cortisol were measured using an ELISA reader (Merck, Japan) according to the standard protocol furnished by the National Institute of Health and Family Welfare (NIHFW, New Delhi, India) [33]. Each testosterone concentration was calculated from a standard curve with five standards supplied by IBL, whereas cortisol concentration was calculated from six standards supplied by NIHFW with absorbance of the standards and samples monitored against a blank at 450 nm. The stated cross-reaction of the testosterone antibody with dehydrotestosterone was 10% and the intra-assay coefficient of variation (CV) was 6.2%. The stated cross-reaction of the cortisol antibody with corticosterone was 10% and intra-assay CV was 5.5%. All the samples were included in a single assay.

2.8. Assays of plasma LH and FSH concentrations

Plasma concentrations of LH were assayed with canine LH RIA kit supplied by Immunotopics International LLC (San Clemente, CA, USA). The canine LH assay is based on the competition between the LH in the sample and a ^{125}I -labeled canine LH tracer for binding to a highly specific rabbit polyclonal antibody of canine LH. After incubation, separation of bound from free is achieved by a second antibody (mouse monoclonal antibody antirabbit IgG). The radioactive bound fraction is precipitated by centrifugation and counted in a gamma counter. The assays were performed following the manufacturer's instructions. The LH concentrations were read from a calibration curve (Calibrators 1–6 supplied with the kit) and expressed as nanograms per milliliter. The minimum detectable concentration has been assayed at 0.39 ng/mL. The intra-assay CV was 3.6%. Plasma concentrations of FSH were assayed with canine FSH immunoradiometric assay (IRMA) kit supplied by Immunotopics International LLC. The canine FSH IRMA is a one-step solid-phase immunoradiometric assay, which offers high affinity and specificity for two different epitopes on FSH. A first monoclonal anti-FSH antibody bound to a polystyrene tube will capture the FSH of the sample in the presence of a second ^{125}I -labeled mouse monoclonal anti-FSH antibody. Following the incubation and the one-step formation of the solid-phase FSH- ^{125}I -labeled monoclonal antibody sandwich, the tube is washed to remove excess unbound labeled antibody. The radioactivity

of the sandwich is directly proportional to the amount of FSH present in the sample. The assays were performed following the manufacturer's instructions. The FSH concentrations were read from a calibration curve (Calibrators 1–6 supplied with the kit) and expressed as nanograms per milliliter. The minimum detectable concentration assayed was 0.2 ng/mL. The intra-assay CV was 3.2%.

2.9. Estimation of total plasma protein concentrations, blood urea nitrogen and fasting blood sugar levels

Total plasma protein concentration was measured according to the standard method of Lowry et al. [34] and the level was expressed as grams per decaliter. Blood urea nitrogen was measured using the kit supplied by Dr. Reddy's Laboratories (diagnostic division), Hyderabad, India, according to the manufacturer's instructions. Fasting blood sugar level was measured using a single-touch glucometer (Blood Life Scan, Johnson and Johnson, Milpitas, CA, USA), and the concentration was expressed as milligrams per 100 mL.

2.10. Assays of testicular key androgenic enzyme activities

The testicular tissue of each animal was used for studying the activities of $\Delta^5,3\beta$ -hydroxysteroid dehydrogenase ($\Delta^5,3\beta$ -HSD) and 17β -hydroxysteroid dehydrogenase (17β -HSD). Testicular $\Delta^5,3\beta$ -HSD activity was assayed spectrophotometrically according to the procedure of Talalay [35]. The activity of testicular 17β -HSD was measured in a UV spectrophotometer according to the procedure of Jarabak et al. [36]. One unit of enzyme activity for $\Delta^5,3\beta$ -HSD and 17β -HSD was considered to be the amount causing a change in absorbance of 0.001/min at 340 nm.

2.11. Assays of testicular glutathione peroxidase, superoxide dismutase and glutathione S-transferase activities

The activity of testicular glutathione peroxidase (GPx) was determined according to the modified procedure described by Paglia and Valentine [37]. GPx present in the sample catalyzes the oxidation of glutathione (GSH) by cumene hydroperoxide, in the presence of glutathione reductase (GSSG-R) and NAD(P)H. The oxidized glutathione [glutathione disulphide (GSSG)] is immediately converted to the reduced form (GSH) with a concomitant oxidation of NAD(P)H to NADP^+ . The decrease in absorbance of NAD(P)H was measured at 340 nm. GPx activity was expressed as nanomolar NAD(P)H oxidized per minute per milligram of protein. Testicular tissue was homogenized in chilled 100 mM sodium phosphate buffer saline (pH 7.4) to give a tissue concentration of 10% (w/v) for the measurement of the activities of superoxide dismutase (SOD) and glutathione S-transferase (GST). The SOD activity was measured spectrophotometrically according to a standard protocol [38]. One unit of SOD activity is defined as the amount of enzyme required to inhibit the rate of 50% NAD(P)H oxidation and expressed as units per

milligram of protein. Glutathione S-transferase activity was measured spectrophotometrically [39] using CDNB (1-chloro-2,4-dinitrobenzene, Sigma, St. Louis, MO, USA) as substrate. The formation of the product of CDNB, *S*-2,4-dinitro-phenyl glutathione, was monitored by measuring the net increase in absorbance at 340 nm against blank. The enzyme activity was calculated using the extinction coefficient $\epsilon=9.6 \text{ M}^{-1} \text{ cm}^{-1}$ and expressed as nanomolar of product formed per minute per milligram of protein. The amount of protein present in the tissue was measured by the method of Lowry et al. [34].

2.12. Estimations of lipid peroxidation from malondialdehyde

The testicular tissue was homogenized (10% w/v) in ice-cold phosphate buffer (0.1 M, pH 7.4) and the homogenate was centrifuged at $15,000\times g$ in 4°C for 3 min. The supernatant was used for the estimation of TBARS and conjugated dienes. TBARS was determined by the reaction of thiobarbituric acid (TBA; Merck, Germany) with malondialdehyde (MDA), a product formed due to the peroxidation of lipids, according to the method of Ohkawa et al. [40]. The amount of TBARS formed was measured by taking the absorbance at 530 nm (extinction coefficient $\epsilon=1.56\times 10^5 \text{ M}^{-1} \text{ cm}^{-1}$) using a UV spectrophotometer (Hitachi, Tokyo, Japan).

2.13. Quantification of testicular contents of GSH and GSSG

GSH and GSSG were determined in the testicular tissues by a modified high-performance liquid chromatography (HPLC) method of McFarris and Reed [41] using UV detection at 365 nm. Tissues were homogenized in 10% perchloric acid containing 1 mM bathophenanthroline disulphonic acid and centrifuged at 10,000 rpm for 5 min in a cold centrifuge. Two hundred and fifty microliters of tissue-acid extract containing internal standard (gamma-glutamyl glutamate) was mixed with 100 μL of 100 mM iodoacetic acid in 0.2 mM cresol purple solution. The acid solution was brought to basic conditions (pH 8.9) by the addition of 0.4 mL of a 4:1, 3 M $\text{KHCO}_3/10 \text{ M KOH}$ mixture and then incubated in the dark at room temperature for 1 h. Rapid *S*-carboxymethyl derivatization of GSH, GSSG and gamma-glutamyl glutamate occurred shortly after the change in pH. *N*-Nitrophenol derivatization of the samples was obtained by incubation for 12 h at 4°C in the presence of 1% 1-fluoro-2,4-dinitrobenzene. Multiple samples were analyzed using the ISCO auto sampler controlled by the ISCO chemical research program (ISCO Model 2350, Lincoln, NE, USA). The sensitivity of the HPLC was 50 pmol/injection volume for GSH and 25 pmol/injection volume for GSSG.

2.14. Statistical analysis

One-way analyses of variance combined with a multiple two-tailed *t*-test with the Bonferroni modification were used

Table 1

Effect of single bilateral intratesticular injection of different doses of CaCl₂ on relative testicular weight, PCV, total plasma protein concentration, fasting blood sugar level and blood urea nitrogen content in male dogs

Condition	Relative testicular weight (mg/100 g body wt)	PCV (%)	Total plasma protein (g/dL)	Fasting blood sugar level (mg/dL)	Blood urea nitrogen (mg/dL)
Control	810±40	30.14±1.46	6.80±0.12	70.12±1.34	12.42±0.84
5 mg/kg body wt. per testis	390±26 ^a	30.86±0.92	6.72±0.18	70.94±1.62	13.10±0.72
10 mg/kg body wt. per testis	114±24 ^b	31.10±1.14	7.14±0.21	71.48±1.81	12.65±1.06
15 mg/kg body wt. per testis	56±12 ^b	31.42±1.85	7.08±0.36	71.82±2.15	13.24±0.94
20 mg/kg body wt. per testis	42±6 ^b	31.18±1.52	7.31±0.48	70.86±1.54	13.56±1.12

Data are shown as mean±S.E, *n*=6.

^a *p*<.01.

^b *p*<.001, as compared with their respective control.

for statistical analysis of the data [42]. Differences were considered significant at *p*<.05, *p*<.01, *p*<.001. Accordingly, a statistical software package (SPSS) was used.

3. Results

Every animal tolerated the intratesticular injections of CaCl₂. They did not suffer from any agitation fever or marked inflammatory swelling of the testis except for a slight increase in firmness of testis on palpation. Most of the dogs showed signs of mild discomfort approximately 1 to 5 min after initiating CaCl₂ as well as normal saline injections, probably caused by fluid pressure. Mild testicular swelling was evident in every dog by 24 h following injection. Swelling was in maximum in treated animals from 48 to 72 h following injection and then gradually decreased at 3 weeks. At 4 weeks after the 20-mg CaCl₂ injection, only a small testicular remnant was palpated. Food consumption was not affected among the five groups of animals throughout the experimental schedule. Every one of the dogs injected with CaCl₂ survived in good healthy condition throughout the experimental period. No marked behavioral changes were noted into the animals during the experimental period. Only after 30 days of intratesticular injection did the animal's behavior become calm and mild tempered.

3.1. Changes in relative testicular weight

A single intratesticular injection of CaCl₂ at doses of 5, 10, 15 or 20 mg led to a graded diminution (*p*<.01) in relative testicular weight compared to the animals in the vehicle control group. This parameter exhibited a greater level of diminution at the 15- and 20-mg dose compared to either the 5- or 10-mg dose treatments (Table 1).

3.2. Effect on fasting blood sugar, blood urea nitrogen, PCV and total plasma protein concentrations

There were no alterations in fasting blood sugar, blood urea nitrogen, PCV or total plasma protein concentration in any of the treated groups with respect to the control group as well as among the four treated groups (*p*>.05; Table 1).

3.3. Changes in histomorphology of testis

Testicular sections showed normal spermatogenesis in vehicle control groups with distinct interstitial spaces (Fig. 1). However, after CaCl₂ treatment, different degrees of degenerative changes in testicular parenchyma were observed. The intratesticular injection of 5 mg CaCl₂ produced disintegration of the germ cell association in seminiferous tubules and washing out of the germ cells from the tubules. Some of the tubules showed the elimination of all germ cells and the presence of only spermatogonia and Sertoli cells. Nevertheless, the induced damage was variable and tubules were not affected uniformly at the lowest dose (Fig. 2). Histomorphological analysis of the testis of the animals treated with 10 mg CaCl₂ showed significant morphological changes, including atrophy of the seminiferous tubules, significant necrosis in the seminiferous

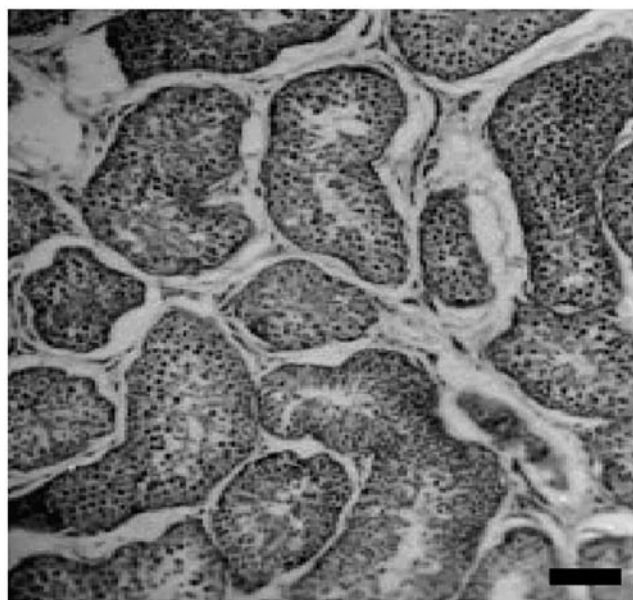


Fig. 1. Photomicrograph of a testicular section 45 days after a single bilateral intratesticular injection of normal saline in a male dog showing the normal arrangement of germ cells in the seminiferous tubules (spermatogenesis) with distinct interstitial space. Bar=100 μ m.

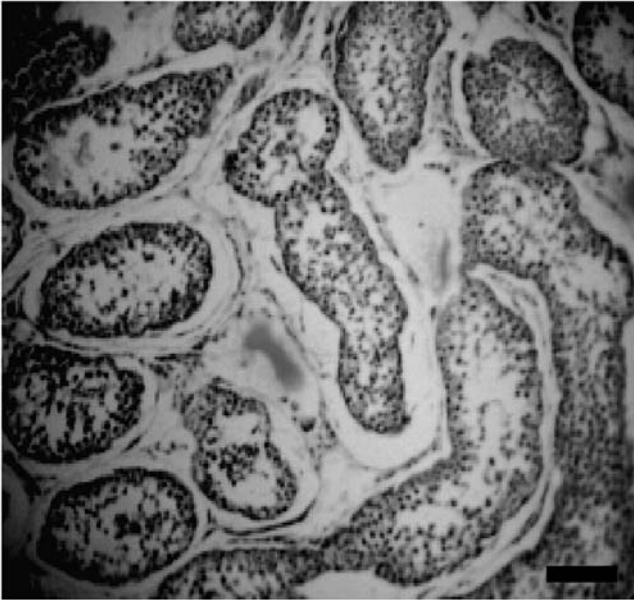


Fig. 2. Photomicrograph of a testicular section 45 days after a single bilateral intratesticular injection of 5 mg CaCl_2 in a male dog showing disintegration of germ cell associations along with washing out of germ cells from the seminiferous tubules. Bar=100 μm .

epithelium and the interstitial spaces as well as presence of degenerated and coagulated germ cells combined with fibrosis in interstitial spaces (Fig. 3). The intratesticular injection of 15 mg CaCl_2 resulted in total necrosis in seminiferous tubules and interstitial Leydig cells, with replacement by a fibrocollagenous band. Complete derangement of the tubular architecture along with infiltration of

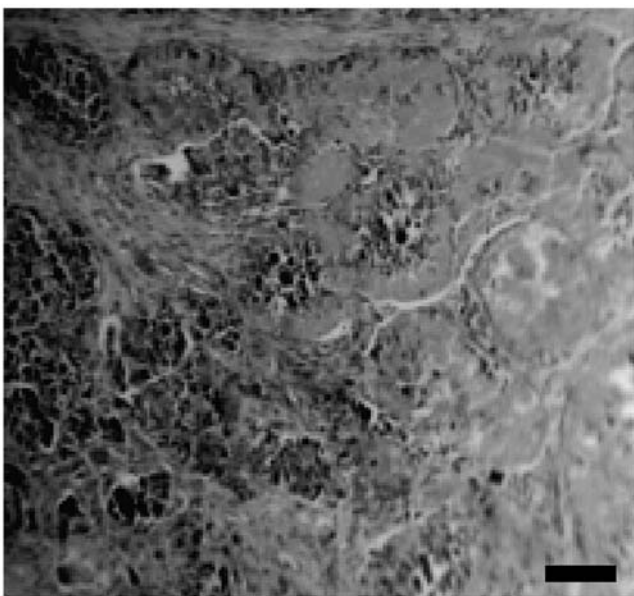


Fig. 3. Photomicrograph of a testicular section 45 days after a single bilateral intratesticular injection of 10 mg CaCl_2 in a male dog showing a high degree of coagulative necrosis in seminiferous tubules and interstitial Leydig cells as well as atrophy of the tubules and fibrosis into the interstitial spaces. Bar=100 μm .

leucocytes throughout the testicular tissue was noted. Mild degree of hyalinization was noted in seminiferous epithelium and interstitial spaces. There was no identification of mature or immature germ cells in testicular sections (Fig. 4). Intratesticular injection of 20 mg CaCl_2 resulted in necrosis of the germinal epithelium and presence only of fibrous tissue and hyaline tissue. Complete derangement of the tubular architecture without any distinct boundary between the tubular and extratubular compartments was noted. There was no identification of mature or immature germ cells in testicular sections. There was no sign of regeneration in germ cells and interstitial Leydig cells (Fig. 5).

3.4. Effect on epididymal sperm count

The epididymal sperm count was decreased significantly ($p < .01$) in all the CaCl_2 -treated rats in comparison to vehicle control animals. Diminution in the numbers of epididymal sperm after 15 or 20 mg of CaCl_2 treatment was more drastic ($p > .001$) compared to other dose treatments (Table 2).

3.5. Effect on plasma concentrations of testosterone and cortisol

A single intratesticular injection of CaCl_2 decreased plasma and intratesticular testosterone concentrations in a dose-dependent manner. A significant ($p < .01$) diminution in plasma and intratesticular concentrations of testosterone was noted in the entire CaCl_2 -treated group in comparison to vehicle control. Moreover, the 15- and 20-mg CaCl_2 treatments also showed a more effective and significant inhibition on these parameters in comparison to the 5- or




Fig. 4. Photomicrograph of a testicular section 45 days after a single bilateral intratesticular injection of 15 mg CaCl_2 in a male dog showing complete derangement of the seminiferous tubular architecture along with the presence of fibrous tissue and hyaline tissue throughout the testicular parenchyma. Bar=100 μm .



Fig. 5. Photomicrograph of a testicular section 45 days after a single bilateral intratesticular injection of 20 mg CaCl₂ in a male dog showing complete necrosis of testicular parenchyma and without any distinct boundary between the tubular and extratubular compartments along with the presence of fibrous tissue and hyaline tissue throughout the testicular parenchyma. Bar=100 μm.

10-mg CaCl₂ treatments. The remarkably low level of plasma and intratesticular concentrations of testosterone was noted in the highest dose of CaCl₂ treatment ($p < .001$; Fig. 6). There was no significant change in plasma concentration of cortisol at any of the doses in comparison to vehicle control as well as among the four treated groups ($p > .05$; Table 2).

3.6. Effect on testicular $\Delta^5,3\beta$ -HSD and 17β -HSD activities

Graded inhibitory responses from CaCl₂ treatments were noted in testicular $\Delta^5,3\beta$ -HSD and 17β -HSD activities. The activities of $\Delta^5,3\beta$ -HSD and 17β -HSD in testicular tissue were decreased significantly ($p < .01$) in all the CaCl₂-treated groups compared to vehicle control. Moreover, the 15- and 20-mg CaCl₂ treatments also exhibited a more

effective and significant ($p < .001$) inhibition on these parameters in comparison to the 5 mg or 10 mg of CaCl₂ treatments (Fig. 6).

3.7. Effect on plasma concentrations of LH and FSH

Intratesticular injection of CaCl₂ enhanced the plasma LH and FSH in a dose-dependent manner. An approximately three-fold increase was observed at the highest dose. Plasma LH and FSH concentrations were significantly ($p < .01$) increased after 10- or 15-mg doses of CaCl₂ injections in comparison to the vehicle-treated control. However, the elevation of these hormone concentrations was not significantly different in 15- and 20-mg CaCl₂ treatments ($p > .05$; Table 2).

3.8. Changes in testicular content of MDA

Testicular content of MDA was elevated ($p < .01$) after treatment with 5 or 10 or 15 mg CaCl₂ compared to the controls, but the 20-mg dose exerted the greatest degree of elevation ($p < .001$) in the testicular content of MDA when compared to the controls. Levels of MDA in the testicular tissue were elevated ($p < .01$) between any of the two groups of 5, 10, 15 or 20 mg of CaCl₂ (Table 2).

3.9. Effect on testicular GPx, GST and SOD activities

A dose-related decrease was associated with testicular GPx, GST and SOD activities. The dose of 15 or 20 mg caused a greater degree of inhibition ($p < .001$) in the activity of these enzymes. Significant inhibition ($p < .01$) in these testicular enzyme activities was noted for every dose from 5 to 20 mg CaCl₂ in comparison to vehicle control. Levels of these enzyme activities in testicular tissue were decreased ($p < .01$) between any of the two groups of 5, 10, 15 or 20 mg of CaCl₂ treatment (Table 3).

3.10. Changes in testicular content of reduced GSH and GSSG

The testicular content of GSH and GSSG was decreased ($p < .01$) in response to CaCl₂ treatment in each of the doses compared to the controls (Tables 2 and 3).

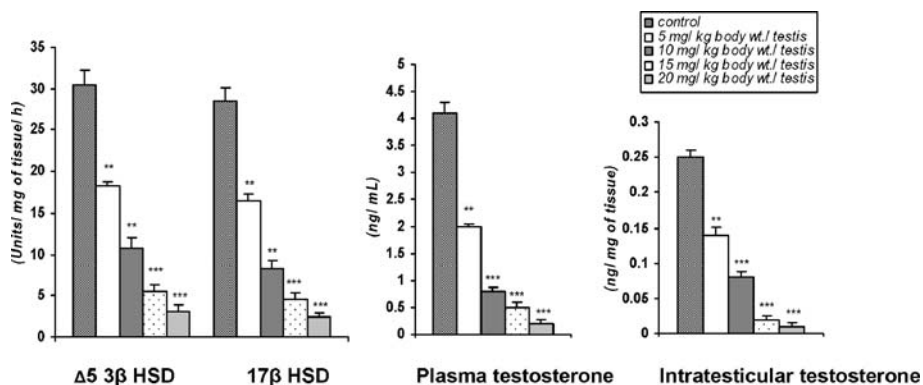


Fig. 6. Bar diagrammatic representation of testicular androgenic key enzyme activities, plasma and intratesticular concentrations of testosterone in mature male stray dogs 45 days after a single bilateral intratesticular injection of different doses of CaCl₂. Data are represented as mean+S.E., $n=12$, ANOVA followed by multiple two-tailed t -test. (** $p < .01$; *** $p < .001$ as compared with respective control).

Table 2

Effect of a single bilateral intratesticular injection of different doses of CaCl₂ on plasma concentrations of LH, FSH and cortisol, epididymal sperm count and testicular contents of MDA, and GSH in male dogs

Condition	LH (ng/mL)	FSH (ng/mL)	Cortisol (μg/mL)	Epididymal sperm count (no./mL)	MDA (nmol/mg of protein)	Reduced GSH (nmol/mg of protein)
Control	2.50±0.21	4.12±0.41	3.12±0.74	8350±630	20.34±0.76	42.56±4.21
5 mg/kg body wt. per testis	3.10±0.34	5.40±0.45	3.40±0.62	1810±245 ^a	28.45±0.84 ^a	18.40±3.12 ^a
10 mg/kg body wt. per testis	4.82±0.36	6.52±0.62	3.84±0.81	128±32 ^b	34.18±0.61 ^a	10.28±2.46 ^b
15 mg/kg body wt. per testis	6.48±0.43	8.68±0.84	4.21±0.68	46±32 ^b	37.62±0.86 ^b	6.04±2.06 ^b
20 mg/kg body wt. per testis	6.80±0.44	8.86±0.2	4.06±0.42	21±5 ^b	38.84±0.74 ^b	3.12±1.84 ^b

Data are shown as mean±S.E., *n* = 6.

^a *p* < .01.

^b *p* < .001, as compared with their respective control.

The ratio of the GSH/GSSG was also decreased with increasing doses of CaCl₂ (Table 3). Moreover, drastic diminutions in these parameters were noted in the 15- and 20-mg CaCl₂ treatments.

4. Discussion

This study revealed a dose-dependent relationship when CaCl₂ was used to induce sterilization in the male dog. The maximum responses in both the biochemical and histological parameters related to chemo-sterilization were noted at the 15- or 20-mg doses. Calcium chloride induces necrosis of the entire testicular tissue. This is in agreement with previous studies with this chemical agent on the testis in the rat [26,27], and in other domestic animals [1]. Testicular palpation after CaCl₂ injection indicated severe degeneration of the testicular tissue, which would likely have rendered the animals infertile. It is believed that the initial testicular swelling is due to edema followed by necrosis of the testicular tissue leading to atrophy of testicular gland parenchyma. The CaCl₂-treated, as well as vehicle-treated, animals showed signs of mild discomfort approximately 1 to 5 min following injection due to the excessive fluid pressure. The signs of discomfort were temporary; none of the dogs licked, bit or rubbed the scrotal area at any time following injection. Moreover, most nerves in the testicular parenchyma are efferent sympathetic nerves that affect the local vasculature [43]. This anatomical arrangement would make pain response from within the testis unlikely [43]. Afferent nerve endings associated with pain sensation are

located in the capsule of the testis [44]. These nerve endings may have been stimulated as intratesticular pressure increased during injection.

Testicular histology also showed degenerative changes associated with graded doses of CaCl₂. Disintegration of germ cell association in seminiferous tubules and washing out of germ cells from the seminiferous tubules were noted even with the lowest dose, although the tubular compartment remained distinct with respect to the extratubular compartment. Drastic necrosis in seminiferous tubules along with atrophy of the tubules was noted with the 10-mg dose. The tubular compartment at this dose was also distinct with respect to the paritubular space. But after high doses (15 or 20 mg) of CaCl₂ treatment, complete degeneration of germ cells together with absence of a distinct boundary of seminiferous tubules with respect to the interstitial spaces along with appearance of fibrous tissue and hyaline tissue was observed. These changes may be due to the necrotizing properties of CaCl₂ as reported by others [45–47]. In addition, germ cell degeneration by CaCl₂ has been associated with low plasma concentrations of testosterone, a prime regulator for the maintenance of structural morphology as well as the normal physiology of seminiferous tubules [48,49]. The induction of testicular degeneration by this chemical agent is supported by the diminution in relative testicular weight in treated dogs, an accepted measure of testicular damage [50].

Graded and significant diminutions in the plasma concentrations of testosterone in response to graded doses of CaCl₂ were correlated to graded diminutions in the

Table 3

Effect of a single bilateral intratesticular injection of different doses of calcium chloride on testicular activities of GPx, GST and SOD, and testicular contents of GSSG along with GSH/GSSG ratio in male dogs

Condition	GPx (U/mg of protein)	GST (U/mg of protein)	SOD (U/mg of protein)	Oxidized glutathione (GSSG) (nmol/mg of protein)	GSH/GSSG ratio
Control	4.62±0.46	3.58±0.36	6.85±0.61	12.10±1.46	3.52±0.31
5 mg/kg body wt. per testis	3.12±0.32 ^a	2.12±0.24 ^a	4.12±0.32 ^a	9.82±1.85 ^a	1.91±0.46 ^a
10 mg/kg body wt. per testis	1.86±0.30 ^a	0.86±0.12 ^a	2.68±0.18 ^a	8.14±1.63 ^a	1.31±0.24 ^a
15 mg/kg body wt. per testis	1.24±0.12 ^b	0.38±0.06 ^b	1.21±0.09 ^b	6.18±1.72 ^b	0.98±0.15 ^b
20 mg/kg body wt. per testis	0.92±0.08 ^b	0.26±0.03 ^b	0.72±0.07 ^b	5.96±1.18 ^b	0.52±0.12 ^b

Data are shown as mean±S.E., *n* = 6.

^a *p* < .01.

^b *p* < .001, as compared with their respective control.

activities of testicular $\Delta^5,3\beta$ -HSD and 17β -HSD, especially as these are key enzymes for testicular androgenesis [51,52].

In addition to this direct effect of CaCl_2 on androgenesis, the plasma concentrations of LH and FSH were significantly increased with each of the effective doses. This may have been due to withdrawal of the negative feedback effect of testosterone on the hypothalamo-pituitary axis [53,54]. The apparent induced chemo-sterilization by CaCl_2 was also supported by elevation in the concentrations of LH and FSH. An increased secretion of gonadotrophins (LH and FSH) was noted following castration in other species of animals [54,55].

Degeneration in the interstitial Leydig cells by graded doses of CaCl_2 may have led to a reduction in plasma testosterone concentrations [56]. The low concentrations of plasma testosterone in the groups treated with CaCl_2 were further evidenced by the qualitative study of testicular sections in which significant fibrosis was seen with the medium and highest doses. These changes were due to low concentrations of testosterone [57]. Moreover, the low plasma concentration of testosterone in CaCl_2 -treated rats has been further indicated by significant diminution in epididymal sperm count as sperm maturation in epididymis is controlled by testosterone [48]. The efficacy of CaCl_2 in inducing chemo-sterilization was supported by the necrosis of seminiferous tubules and interstitial cells, along with significant fibrosis and hyalinization. These effects are consistent with previous studies using other chemical agents for chemo-sterilization [15,23]. Infiltration of leucocytes into the seminiferous tubules and interstitial spaces after treatment with the highest dose may have been due to damage of the testicular tissue or to degeneration that may have released large amounts of chemotactic factors responsible for the ingress of leucocytes [24].

Another way by which chemo-sterilization may be induced with CaCl_2 could be through the generation of large amounts of free radicals, or their products, in the testicular tissue. Free radical production in the testis results in low level of testosterone [58,59]. CaCl_2 is also an important chemical agent for inducing the generation of free radicals in tissues [60]. Free radicals can cause the destruction of all cellular structures and of lipids by lipid peroxidation [61]. The extent of lipid peroxidation and, consequently, the associated tissue damage can be assessed by the measurement of TBARS and conjugated dienes [62]. The fact that an intratesticular injection of CaCl_2 was associated with free radical production and lipid peroxidation in the testis was reflected by the high testicular content of TBARS and conjugated dienes. The alternative way by which free radicals may be generated in the testis would be through the infiltration of leucocytes. Testicular free radical production was closely associated with the infiltration of leucocytes [63].

The elevation in the formation of free radicals in testes treated with calcium chloride is also supported by the

diminution in testicular GPx, SOD and GST activities, as these are considered important scavenging enzymes against free radicals in male gonads [64,65]. Besides these enzymatic antioxidants, CaCl_2 treatment was also associated with a lowered content of testicular reduced GSH, as important nonenzymatic antioxidant in testis [66]. The low activities of testicular GPx, SOD and GST along with a low content of GSH among the treated dogs may have been due to the lowered concentrations of testosterone [58,59]. It may be assumed that testicular degeneration in this experiment was due to generation of free radicals in the testis as free radicals are inhibitors for spermatogenesis [30] and testicular androgenesis [67]. In addition, the reduced levels of GST activity and GSH content in the testes would be another cause for the degenerative necrosis of seminiferous tubules. GST and GSH are important regulators for the proliferation and differentiation of germ cells and provide protection of germ cells against the harmful effects of free radicals [68,69]. However, Bauche et al. [70] showed that Sertoli and peritubular cells have a high content of GSH and high activity of GST. Degeneration of these cells by calcium chloride treatment could be a possible cause of the lower content of GSH and GST activity in the treated testis. The testicular GSH/GSSG ratio, an index of tissue oxidative stress [71], also decreased with increasing calcium chloride dose, further suggesting dose-dependent oxidative testicular degeneration in dogs caused by intratesticular injection of CaCl_2 . The observed decreases in the levels of enzymatic and nonenzymatic antioxidants are consistent with our past studies [1,26,27].

The stress indicators including the concentrations of plasma cortisol, total plasma protein, blood urea nitrogen, fasting blood sugar and PCV were measured to ascertain whether the CaCl_2 treatment was associated with any chronic stress response in the experimental animals. Almost any type of stress will cause an increase in the secretion of cortisol in the dog [72]. Cortisol is established as an indicator of stress [4]. As there were no significant alterations in the plasma concentrations of cortisol, blood urea nitrogen, fasting blood sugar level, PCV or total plasma protein concentrations in the animals treated with CaCl_2 compared to the controls, this method of chemo-sterilization does not appear to be associated with any chronic stress response, which is also supported by our previous findings [1,26,27].

It is suggested that the chemo-sterilization that developed by intratesticular injection of CaCl_2 might be caused by a high rate of free-radical generation in the testicular tissues and a low level of testosterone.

5. Conclusion

An intratesticular injection of CaCl_2 was effective and economical for the sterilization of male dogs. It is free from pain and chronic stress and will contribute to a simple alternative method to surgical castration.

Acknowledgments

The authors would like to acknowledge the Indian Council of Agricultural Research (ICAR) for the financial support and are also thankful to Prof. M.K. Bhowmik, Director of Research, Extension and Farms West Bengal University of Animal and Fishery Sciences, Calcutta, for his interest in this study.

References

- [1] Jana K, Ghosh D, Samanta PK. Evaluation of single intratesticular injection of calcium chloride for non-surgical sterilization of male goats (*Capra hircus*): a dose dependent study. *Anim Reprod Sci* 2005;86:89–108.
- [2] Huber DH, Hong S, Ross JA. The international experience with vasectomy. In: Zatuchni GI, Goldsmith A, Spieler JM, editors. *Male contraception: advances and future prospects*. Philadelphia: Harper & Row; 1986. p. 7–8.
- [3] Liu X, Li S. Vasal sterilization in China. *Contraception* 1993;48:255–63.
- [4] Cohen RDH, King BD, Thomas LR, Janzen ED. Efficacy and stress of chemical versus surgical castration of cattle. *Can J Anim Sci* 1990;70:1063–72.
- [5] Wiebe JP, Barr KJ. The control of male fertility by 1,2,3-trihydroxypropan (THP; glycerol): rapid arrest of spermatogenesis without altering libido, accessory organs, gonadal steroidogenesis and serum testosterone. LH and FSH. *Contraception* 1984;29:291–302.
- [6] Matsumoto AM. Is high dosage of testosterone an effective male contraceptive agent? *Fertil Steril* 1988;50:324–8.
- [7] Swerdloff RS, Wang C, Bhasin S. Developments in the control of testicular function. *Baillieres Clin Endocrinol Metab* 1992;6:451–83.
- [8] Dhar JD, Setty BS. Effect of a nonsteroidal antiandrogen, anandron, on the reproductive system and fertility in male rats. *Contraception* 1990;42:121–8.
- [9] Wu FCW. Male contraception: current status and future prospects. *Clin Endocrinol* 1988;29:443–65.
- [10] Wu FCW, Aitken RJ. Suppression of sperm functions by depot-metroxyprogesterone acetate and testosterone enanthate in steroid male contraception. *Fertil Steril* 1989;29:443–65.
- [11] Trembley Y, Belanger A. Reversible inhibition of gonadal functions by a potent gonadotrophin releasing hormone agonist in adult dog. *Contraception* 1984;30:483–97.
- [12] Dube D, Assaf A, Pelletier G. Morphological study of the effects of an GnRH agonist on the canine testis after 4 months of treatment and recovery. *Acta Endocrinol (Copenh)* 1987;116:413–7.
- [13] Dowsett KF, Pattie WA, Knott LM. A preliminary study of immunological castration in colts. *J Reprod Fertil* 1991;44(Suppl):183–90.
- [14] Gonzalez A, Allen AF, Post AK. Immunological approaches to contraception in dogs. *J Reprod Fertil Suppl* 1989;39:189–98.
- [15] Parizek J. Sterilization of the male by cadmium salts. *J Reprod Fertil* 1960;1:294–309.
- [16] Kar AB. Chemical sterilization of male rhesus monkeys. *Endocrinol* 1961;69:1116–9.
- [17] Kar AB, Kamboj VP, Goswami A. Sterilization of male rhesus monkeys by iron salts. *J Reprod Fertil* 1965;9:115–7.
- [18] Fahim MS, Wang M, Sutcu MF. Sterilization of dog with intra-epididymal injection of zinc arginine. *Contraception* 1993;47:107–22.
- [19] Dixit VP, Lohiya NK, Arya M, Argrawal M. Chemical sterilization of male dogs after a single testicular injection of 'Danazol'. *Folia Biol* 1973;23:305–10.
- [20] Naz RK, Talwar GP. Immunological sterilization of male dogs by BCG. *Int J Androl* 1981;4:111–28.
- [21] Wiebe JP, Barr KJ, Buckingham KD. Sustained azospermia in the squirrel monkey, *Saimiri sciureus*, resulting from a single intratesticular glycerol injection. *Contraception* 1989;39:447–57.
- [22] Fordyce G, Hodge PB, Beaman NJ, Leing HR, Compro C, Sheherd RK. An evaluation of calf castration by intratesticular injection of a lactic acid solution. *Aust Vet J* 1989;66:272–6.
- [23] Immegart HM, Threlfall WR. Evaluation of intratesticular injection of glycerol for non-surgical sterilization of dogs. *Am J Vet Res* 2000;61:544–9.
- [24] Heath E, Arowolo R. The early histopathologic effects of intratesticular injection with hyperosmolar glycerol, glucose or NaCl solutions. *Andrologia* 1987;19:654–61.
- [25] Gunn SA, Gould TC. Cadmium and other mineral elements. In: Johnson AD, Gomes WR, Van Demark NL, editors. *The testis*, vol III. New York: Academic Press; 1970. p. 377–481.
- [26] Jana K, Samanta PK, Ghosh D. Dose dependent response to an intratesticular injection of calcium chloride for induction of chemosterilization in adult albino rats. *Vet Res Commun* 2002;26:651–73.
- [27] Jana K, Samanta PK. Evaluation of single intratesticular injection of calcium chloride for non-surgical sterilization in adult albino rats. *Contraception* 2006;73:289–300.
- [28] O'Conner JJ. *Dollar's veterinary surgery*. London: Bailliere Tindall; 1938.
- [29] American Veterinary Medical Association. Panel on Euthanasia. *J Am Vet Med Assoc* 2001;218:669–96.
- [30] Alvarez JG, Story BT. Assessment of cell damage caused by spontaneous lipid peroxidation in rabbit spermatozoa. *Biol Reprod* 1984;30:323–31.
- [31] Samanta L, Chainy GBN. Comparison of hexachloro-cyclohexane induced oxidative stress in the testis of immature and adult rats. *Comp Biochem Physiol* 1997;118:319–27.
- [32] Tohda A, Matsumiya K, Tadokoro Y, Yomogida K, Miyagawa Y, Dohmae K. Testosterone suppresses spermatogenesis in juvenile spermatogonial depletion (jsd) mice. *Biol Reprod* 2001;5:532–7.
- [33] Srivastava TG. Enzyme linked immunosorbent assay for steroid hormones. In: Srivastava TG, Misro MM, editors. *Orientation training course on research methodology in reproductive biomedicine*. New Delhi: National Institute of Health and Family Welfare; 2003. p. 55–8.
- [34] Lowry OH, Rosebrough NJ, Farr AL, Randall RJ. Protein measurement with Folin-phenol reagent. *J Biol Chem* 1951;193:265–75.
- [35] Talalay P. Hydroxysteroid dehydrogenase. In: Colowick SP, Kaplan NO, editors. *Methods in enzymology*, vol 5. New York: Academic Press; 1962. p. 512–6.
- [36] Jarabak J, Adams JA, Williams-Ashman HG, Talalay P. Purification of a 17 β -hydroxysteroid dehydrogenase of human placenta and studies on its transhydrogenase function. *J Biol Chem* 1962;237:345–57.
- [37] Paglia DE, Valentine WN. Studies on quantitative and qualitative characterization of erythrocyte glutathione peroxidase. *J Lab Clin Med* 1967;70:158–69.
- [38] Paoletti F, Macoli A. Determination of superoxide dismutase activity by purely chemical system based on NAD(P)H oxidation. In: Packer L, Glazer AN, editors. *Methods in enzymology*, vol 186. New York: Academic Press; 1990. p. 209–20.
- [39] Habig WH, Pabst MJ, Jacoby WB. Glutathione S-transferase: the first step in mercapturic acid formation. *J Biol Chem* 1974;249:7130–9.
- [40] Ohkawa H, Ohishi N, Yagi K. Assay for lipid peroxides in animal tissues by thiobarbituric acid reaction. *Anal Biochem* 1979;95:351–8.
- [41] McFarris W, Reed DJ. High performance liquid chromatography of thiols and disulfides: dinitrophenol derivatives. *Methods Enzymol* 1987;143:101–9.
- [42] Das D. Analysis of variance. In: Das D, Das A, editors. *Statistics in biology and psychology*. Calcutta: Academic Publisher; 1998. p. 250–82.
- [43] Christensen GC. The urogenital apparatus. In: Evans HE, Christensen GC, editors. *Miller's anatomy of dog*. Philadelphia: WB Saunders Company; 1979. p. 544–601.

- [44] Davis JR, Langford GA, Kirby PJ. The testicular capsule. In: Johnson WR, Gomes WR, editors. The testis. New York: Academic Press Inc; 1970. p. 285–93.
- [45] Koger LM. Calcium chloride for the prevention of horn bud growth in calves. *J Vet Med Assoc* 1976;169:219–21.
- [46] Albers GW, Theilen GH. Calcium chloride for treatment of subcutaneous lipomas in dogs. *J Am Vet Med Assoc* 1985;186:492–4.
- [47] McGinnis KM, Wangi KK, Genegy ME. Alterations of extra-cellular calcium elicits selective modes of cell death and protease activation in SH-SY5Y human neuroblastoma cells. *J Neurochem* 1999;72:1853–63.
- [48] Sharpe RM, Maddocks S, Millar M, Saunders PTK, Kerr JB, McKinnell C. Testosterone and spermatogenesis: identification of stage dependent, androgen-regulated proteins secreted by adult rat seminiferous tubules. *J Androl* 1992;13:172–84.
- [49] Kerr JB, Millar M, Maddocks S, Sharpe RM. Stage dependent changes in spermatogenesis and Sertoli cells in relation to the onset of spermatogenic failure following withdrawal of testosterone. *Anat Rec* 1993;235:547–59.
- [50] Foote RH, Schermerhorn EC, Simikili ME. Measurement of semen quality, fertility and reproductive hormones to assess dibromochloropropane (DBCP) effects in live rabbits. *Fundam Appl Toxicol* 1986;6:628–37.
- [51] Ohba H, Inano H, Tamaoki B. Kinetic mechanism of porcine testicular 17 β -hydroxy steroid dehydrogenase. 1982;17:381–9.
- [52] Ishii-Ohba H, Saiki N, Inano H, Takemori B. Purification and properties of testicular 3 β -hydroxysteroid dehydrogenase and 5-ene-4-ene-isomerase. *J Steroid Biochem* 1986;25:255–60.
- [53] Plant TM. Effects of orchidectomy and testosterone replacement treatment on pulsatile luteinizing hormone secretion in the adult rhesus monkey (*Macaca mulatta*). *Endocrinol* 1982;110:1905–13.
- [54] Tillbrook AJ, Clarke IJ. Negative feedback regulation of the secretion and actions of gonadotrophins releasing hormone in males. *Biol Reprod* 2001;64:735–42.
- [55] Tillbrook AJ, Clarke IJ. Negative feedback regulation of the secretion and actions of GnRH in male ruminants. *J Reprod Fertil Suppl* 1995;49:297–306.
- [56] Johnson L, Thomson Jr DL. Effect of seasonal variation in Leydig cell number on the volume of smooth endoplasmic reticulum in Leydig cells and intratesticular testosterone content in stallions. *J Reprod Fertil* 1987;81:227–2231.
- [57] Jegou B, Sharpe RM. Paracrine mechanism in testicular control. In: Dekrester D, editor. *Molecular biology of male reproduction*. London: Academic Press; 1993. p. 271–95.
- [58] Peltola V, Huhtaniemi I, Metsa-Ketla T, Ahotupa M. Induction of lipid peroxidation during steroidogenesis in rat testis. *Endocrinol* 1996;137:105–12.
- [59] Chainy GBN, Samantaray S, Samanta L. Testosterone induced changes in testicular antioxidant system. *Andrologia* 1997;29:343–50.
- [60] Kakkar P, Mehrotra S, Viswanthan PN. Inter-relation of active oxygen species, membrane damage and altered calcium functions. *Mol Cell Biochem* 1992;111:11–5.
- [61] Halliwell B, Gutteridge JMC. *Free radicals in biology and medicine*. Oxford: Clarendon Press Inc; 1985.
- [62] Gutteridge JMC. Lipid peroxidation and antioxidants as biomarkers of tissue damage. *Clin Chem* 1995;41:1819–28.
- [63] Aitken RJ, West KM. Analysis of the relationship between ROS production and leukocyte infiltration in fraction of human semen separated on percoll gradients. *Int J Androl* 1990;13:433–51.
- [64] Samanta L, Roy A, Chainy GBN. Changes in rat testicular antioxidant defense profile as a function of age and its impairment by hexachlorocyclohexane during critical stages of maturation. *Andrologia* 1999;31:83–90.
- [65] Rao AVSK, Shaha C. Role of glutathione S-transferase in oxidative stress-induced male germ cell apoptosis. *Free Radic Biol Med* 2000;29:1015–27.
- [66] Grosshans K, Calvin HI. Estimation of glutathione in purified populations of mouse testis germ cells. *Biol Reprod* 1985;33:1197–205.
- [67] Georgiou M, Parkins LM, Payne AH. Steroid synthesis-dependent, oxygen-mediated damage of mitochondrial and microsomal cytochrome P-450 enzymes in rat Leydig cell cultures. *Endocrinol* 1987;121:1390–9.
- [68] Aravinda S, Gopalakrishnan B, Shaha C. Testicular GST in germ cell proliferation. In: Sengupta J, Ghosh D, editors. *Cellular and molecular signaling in reproduction*. New Delhi: New Age International Publishers; 1996. p. 1–10.
- [69] Gopalakrishnan B, Shaha C. Inhibition of sperm glutathione S-transferase leads to functional impairment due to membrane damage. *FEBS Lett* 1998;422:296–300.
- [70] Bauche F, Fonchard M, Jegou B. Antioxidant system in rat testicular cells. *FEBS Lett* 1994;349:392–6.
- [71] Warner P, Cohen G. Glutathione disulfide (GSSG) as a marker of oxidative injury to brain mitochondria. *Ann N Y Acad Sci* 1993;679:364–9.
- [72] Guyton AC, Hall JE. The adrenocortical hormones. In: Guyton AC, Hall JE, editors. *Textbook of medical physiology*. New York: W.B. Saunders Company; 1996. p. 963–4.